

# Use of the Endoscopic Forehead-Lift to Improve Brow Position in Persistent Facial Paralysis

Yadranko Ducic, MD, FRCSC; Robert Adelson, MD

**T**raditionally, the asymmetrical brow in facial paralysis has been treated with open procedures. There are few data that support the use of endoscopic procedures to treat patients with facial palsy or paralysis. We sought to evaluate a single surgeon's experience with the use of endoscopic forehead-lifts to treat asymmetrical brow positioning resulting from facial nerve disorders. All cases involving patients who underwent endoscopic brow-lifts by the senior author (Y.D.) from 1997 through 2003 with a minimum follow-up of 12 months were retrospectively reviewed. Demographic data were collected, and patient satisfaction was determined from postoperative interviews conducted at follow-up visits. Standard photographs were used to measure the degree of preoperative and postoperative brow asymmetry. A total of 31 cases were available for review. The average age of our patient population was 47 years (age range, 22-76 years), with a male-female ratio of almost 1.5:1. Twenty-three patients had a complete paralysis, and 8 patients had a palsy. The average preoperative difference in height at the desired apex of brow was 5.9 mm, with a range of 3.0 to 9.0 mm. The average postoperative difference (as measured at 12 months) in brow position was only 1.3 mm, with a range of 0 to 3 mm. Adjunctive periorbital procedures were performed in the majority of patients (90%) at the time of endoscopic brow-lifting. All patients felt that their brow position was much improved after surgery. No major complications were encountered. A single patient underwent a secondary open direct browpexy to optimize his result. Endoscopic brow-lifting may be associated with favorable outcomes in the majority of patients with facial nerve palsy or paralysis. Performing concurrent adjunctive periorbital procedures as deemed necessary to optimize lower eyelid position, eyelid closure, and upper eyelid symmetry appears to be safe and reliable. *Arch Facial Plast Surg. 2005;7:51-54*

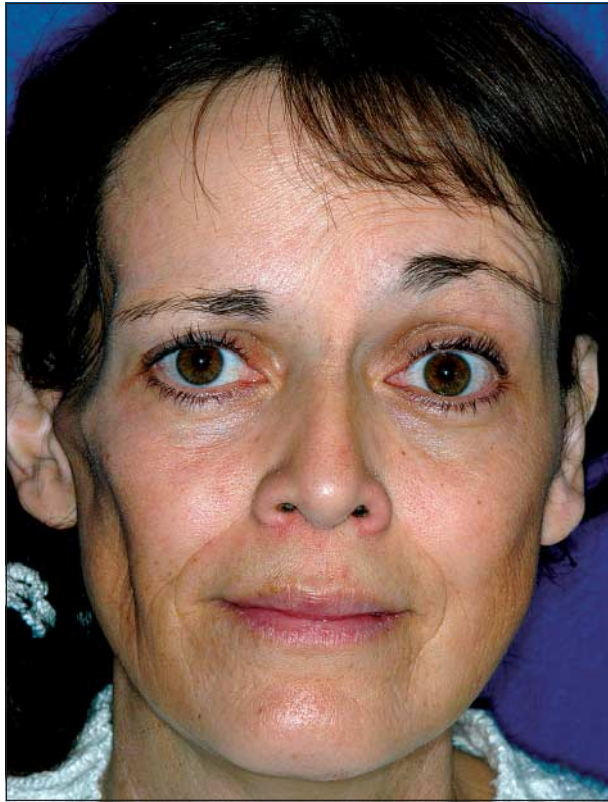Over the past 20 years, as instrumentation has improved, there has been a tremendous expansion of endoscopic techniques and minimal-access approaches in a diverse spectrum of surgical procedures. However, early surgeons have been pursuing these techniques for a number of years. Endoscopic (derived from the Greek words *endon* [within] and *skopein* [to view]) surgery, in its most basic form, consists of viewing internal structures from a distance for diagnosis or alteration. Babylonian texts, in 65 BC, describe visualizing the cervix through a lead funnel connected to a bent mouthpiece.<sup>1</sup> Modern endoscopic techniques rely on the provision of a light source to illuminate distal cavities. In 1807, Bozzini developed the

first light reflector, which allowed refracted rays to pass from the illuminated cavity to the surgeon's eye.<sup>2</sup>

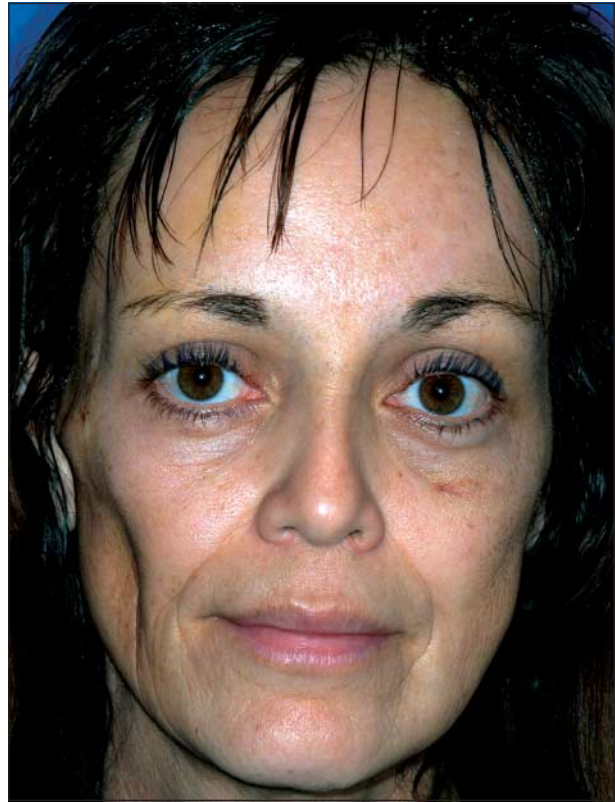Rehabilitation in cases involving patients with facial paralysis often requires precise and directed treatment of multilevel asymmetry. Both dynamic and static procedures may have a role to play in the surgical treatment of this patient population. Unilateral facial paralysis results in a lack of resting tone in the facial musculature. In an effort to compensate for these inactive or severely hypotonic (in the case of palsy) muscles, there is often hyperactivity of the contralateral functioning facial muscles, leading to further exaggeration of the visual deformity. By repositioning the soft tissues overlying these muscles, in a static manner, it may be possible to achieve a significant improvement in facial symmetry.

The brow forms a prominent esthetic highlight of the face, framing the perior-

**Author Affiliations:** Department of Otolaryngology-Head and Neck Surgery, The University of Texas Southwestern Medical Center, Dallas; and Division of Otolaryngology and Facial Plastic Surgery, John Peter Smith Hospital, Fort Worth, Tex.



**Figure 1.** Preoperative appearance of patient with significant right-sided brow ptosis and contralateral frontalis hyperactivity related to extirpation of skull base malignancy. The frontal view shown is at rest with eyes open.



**Figure 2.** Postoperative view of patient in Figure 1 at 1 year showing improved brow position and significant relaxation of frontalis hyperactivity.

bital area. Its position is determined by the balance between the brow depressors (corrugator supercilii, depressor supercilii, and orbicularis oculi muscles) and the primary brow elevator (occipitofrontalis muscle sling), all of which are innervated by the facial nerve. With facial nerve paralysis, there is brow ptosis as a result of unopposed gravity as well as variable asymmetry as a result of contralateral muscular hyperactivity. Traditional approaches to esthetic enhancement of the ptotic brow have included coronal, pretrichial, midforehead, and brow incisions.<sup>3</sup> In the early 1990s, Isse<sup>4</sup> popularized endoscopic forehead-lifting via minimal-access incisions. In contradistinction to older techniques, which all relied to some extent on excision of skin at or above the level of the brow in order to effect a change in position, endoscopic release of the depressor muscles and soft tissue attachments at the supraorbital rim and temporal line allows a more functional and physiologic elevation of brow position. This release takes advantage of the upward pull provided by the occipitofrontalis muscle.

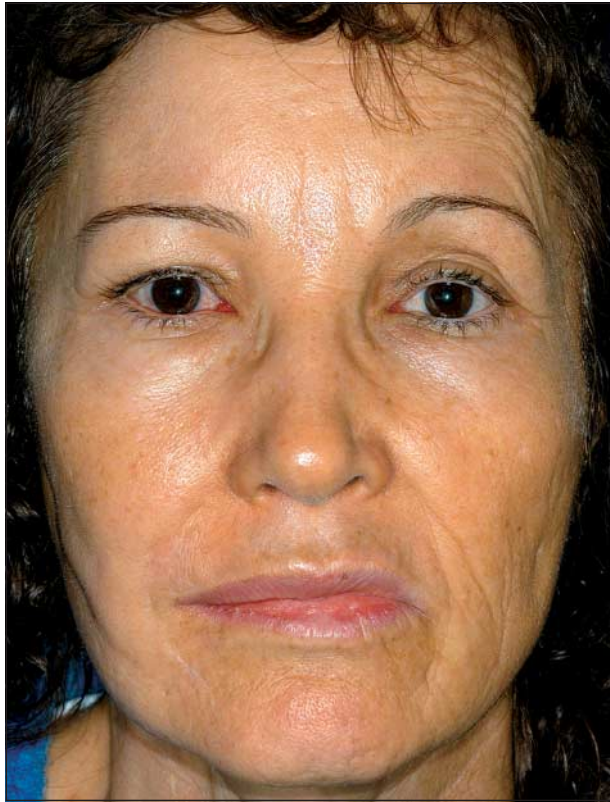
Herein, we review our favorable experience with endoscopic forehead-lifting to improve the appearance of patients with facial paralysis or palsy.

## METHODS

All cases involving patients who underwent endoscopic brow-lifting for facial palsy or paralysis that resulted in significant asymmetry were reviewed in a retrospective fashion. The review included the senior author's (Y.D.) consecutive series (1997-2003) with a minimum follow-up of 12 months. Demographic

data and preoperative and postoperative photographs were examined, and an in-person and/or telephone interview was conducted with each patient to gauge patient satisfaction with the procedure and the outcome (**Figures 1, 2, 3, and 4**).

The patients' foreheads are marked in the holding area before anesthesia is administered. The point of maximal brow elevation is located along an imaginary line that extends from the lateral aspect of the ala through the midpupillary line at centric gaze. The difference in height between the brows at this point is measured. Access incisions are centered on either side of this point of maximal elevation. Thus, 2 paramedian incisions are planned per side to allow maximal brow support in the early postoperative period. Also, a temporal incision is planned to access the temporal fossa. The temporal incision is posttrichial and is centered over a line that extends from the ala through the lateral canthus. The supratarsal crease is also marked. General anesthesia is used in all patients who undergo the procedure. After induction, supraorbital and supra-trochlear nerve blocks are performed with 1% lidocaine with 1:100,000 epinephrine solution. Planned access incisions are directly infiltrated with the same solution. After enough time has passed for the vasoconstrictive effect to occur, a 1.5-mm drill bit with a 4-mm stop is used to mark the outer cortex of the calvarium at the anterior aspect of each of the paramedian incisions. Next, occipital and frontal elevation is performed in a subperiosteal manner. The frontal elevation proceeds to within 2 cm of the supraorbital rim, at which point a 30° endoscope with an irrigating sheath is used to completely release the periosteal attachments at the level of the supraorbital rim, while the supraorbital nerves are identified and preserved. Medially, the dissection proceeds onto the radix. Laterally, the temporal access incision allows dissection in a plane superficial to the deep temporal fascia to the edge of the temporal fossa, passing from there into the central dissection pocket. With brow release completed, a caliper is used to precisely measure the

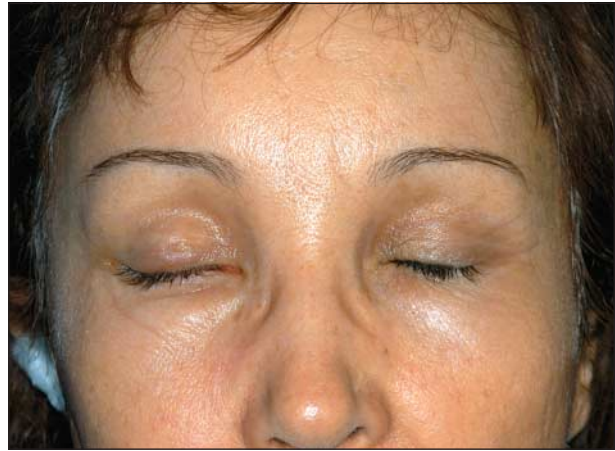

**Figure 3.** Preoperative appearance of patient with right-sided brow ptosis and corneal exposure as well as contralateral frontalis hyperactivity related to surgical removal of an aggressive parotid carcinoma. The frontal view shown is at rest with eyes open.

amount of desired differential brow elevation on the normal (some degree of age-related brow ptosis is often seen) and affected sides (based on preoperative measurements). The drilled mark that was made before elevation is now used as the anterior register point. Again, a 1.5-mm drill bit with a 4-mm stop is used to make the posterior hole, into which a 14-mm-long titanium screw is inserted. Surgical staples, which are placed posterior to this titanium post, then secure the brow elevation. Generally, no dressings are applied. Retention screws are removed at 2 weeks.

## RESULTS

A total of 31 patients with facial nerve palsy or paralysis underwent endoscopic brow-lifts from 1997 to 2003 with a minimum follow-up of 12 months. The average age of our patient population was 47 years (age range, 22-76 years) with a male-female ratio of almost 1.5:1. The source of the facial nerve disorder was neoplasm and its removal in 22 patients, Bell palsy in 8 patients, and infection in 1 patient. Twenty-three patients had a complete paralysis, and 8 patients had a palsy. The average preoperative difference in height at the desired apex of brow elevation was 5.9 mm, with a range of 3.0 to 9.0 mm. The average postoperative difference (as measured at 12 months) in brow position was only 1.3 mm, with a range of 0 to 3 mm. Adjunctive periorbital procedures were performed in the majority of patients (90%) at the time of endoscopic brow-lifting. These procedures consisted of upper eyelid gold weight insertion (n=24), lower eyelid-tightening proce-



**Figure 4.** Postoperative view of patient in Figure 3 at 1 year showing improvement in brow symmetry, decrease in frontalis hyperactivity, and good eyelid closure as a result of gold weight insertion.

dures (tarsal strip [n=14], suture-only suspension [n=4], and orbicularis muscle sling [n=5]), and conservative upper blepharoplasty with excision of excess redundant skin (n=12). We did not encounter any significant difficulties in performing concurrent adjunctive procedures. All patients thought that their brow position was much improved after surgery. No major complications were encountered. A single patient underwent a secondary open direct browpexy to optimize his result. No other brow procedures, surgical or chemical, were subsequently performed in our patient population. Delayed exposure of the gold weight, which was subsequently replaced without incident, occurred in 1 patient (6 months after insertion). We did not note any significant differences in esthetic outcome as related to age of patients, source of palsy or paralysis, or degree of paralysis. We did note esthetically pleasing relaxation of the contralateral frontalis hyperactivity once the brow position had been optimized. This result contributed tremendously to the postoperative outcome in affected patients.

## COMMENT

Age- or palsy-related ptosis of the forehead is addressed most often by brow-lifting and less commonly by chemical denervation of hyperactive musculature.<sup>5</sup> Chemical denervation, lasting generally no more than 3 to 4 months, may be a useful temporizing measure until the patient is willing and able to tolerate a more definitive surgical procedure to reestablish brow position.

Both open and endoscopic brow-lifts will result in lasting favorable alterations in brow position, with no statistically significant differences noted between the 2 techniques.<sup>6</sup> Differing planes of dissection have been used in endoscopic brow-lifting. The 2 commonly used planes of dissection are the subgaleal and the subperiosteal.<sup>7-9</sup> We favor the latter approach because of the ease and safety of dissection and the lack of unnatural forehead activity that occasionally occurs with the variable adherence of the elevated flap to the underlying pericranium in subgaleal dissections. As a consequence of open brow-lifting, alterations in brow position result from skin re-

section, whereas with endoscopic techniques, these alterations arise as a result of functional muscle pull. There must be some support provided to the elevated brow during the time required for adequate adherence of the periosteum to the underlying calvarium (in a more superior position). This support has been successfully provided by simple dressings, K-wire fixation, subperiosteal tunnels, resorbable screws and tacks, and temporary transcutaneous titanium screw fixation.<sup>10-13</sup> We prefer the latter technique, as we believe that it provides the most accurate differential stable brow fixation of any of the available techniques. It has been well tolerated and accepted by our patient population.

Traditionally, the patient with unilateral brow ptosis due to facial paralysis has been treated with a direct brow-lift through a transcutaneous suprabrow incision. In our experience, the scar heals in an unpredictable manner. It can vary from imperceptible to quite pronounced, despite meticulous closure techniques. Most often, it is noticeable and not easily camouflaged with makeup or other techniques. In an effort to avoid this scarring, some authors have proposed direct browpepxy via small scalp incisions.<sup>14</sup> In our hands, both this technique and internal browpepxy performed through an upper blepharoplasty incision are useful adjuncts in cases involving patients with minimal brow ptosis. However, it is difficult to accurately correct significant asymmetrical brow ptosis using these techniques. Furthermore, they do not address the contralateral muscular hyperactivity that is often seen in such cases, which contributes significantly to the final esthetic outcome.

Frontal branch neurectomy, open or endoscopic, has been reported to be an option to address contralateral occipitofrontalis sling hyperactivity.<sup>15</sup> We believe that neurectomy is generally not required, as the hyperactivity is often no longer a significant problem once enhanced brow symmetry has been established. Furthermore, neurectomy does not completely address the issue of palsy, in which case a complete contralateral neurectomy may exacerbate the patient's deformity. Takushima et al<sup>16</sup> have reported favorable outcomes with unilateral brow-lifting in young patients "whose brow ptosis is minor"; however, they found that this procedure was relatively ineffective in older patients and in patients with more severe brow ptosis. Our results do not support their conclusions. We believe that the difference in outcomes is related to the fact that we completely release and elevate both eyebrows with our endoscopic technique as opposed to treating only the affected side. Rautio and Pignatti,<sup>17</sup> reporting on a small series of patients with facial paralysis who were treated with various fixation methods, found a 20% relapse rate as well as a case of glabellar sloughing in patients who were treated with the endoscopic technique. They deferred any adjunctive periorbital procedures to a second stage for fear of causing lagophthalmus. Almost our entire study group underwent adjunctive simultaneous periorbital procedures, without deleterious effect. Also, we did not note any significant long-term relapse of the asymmetry with a minimum fol-

low-up period of 1 year. There was some settling of bilateral brow position during the first 3 months after the procedure, but the newly established difference in height between the 2 eyebrows remained constant.

## CONCLUSIONS

Endoscopic brow fixation appears to be associated with a predictable, pleasing, long-term amelioration of brow asymmetry in the majority of patients with palsy or paralysis of the facial nerve. A bilateral procedure enhances the outcome by addressing contralateral occipitofrontalis hyperactivity more completely. Adjunctive reconstructive periorbital procedures, including blepharoplasty, gold weight insertion, and lower eyelid-tightening procedures, may be safely and reliably performed at the same time as endoscopic brow-lifting. The results, in terms of improvement in asymmetry, appear to last and are well accepted and tolerated by our patient population.

Accepted for Publication: September 22, 2004.

Correspondence: Yadranko Ducic, MD, FRCSC, Division of Otolaryngology and Facial Plastic Surgery, 1500 S Main St, Fort Worth, TX 76104 (yducic@sbcglobal.net).

## REFERENCES

1. Semm K. Introduction. In: Sanfilippo J, Levine R, eds. *Operative Gynecologic Endoscopy*. New York: Springer Verlag NY Inc; 1989:1-10.
2. Fodor PB, Rosenberg PH. Endoscopically assisted aesthetic plastic surgery. In: *Endoscopic Forehead Lifting*. St Louis, Mo: Mosby-Year Book Inc; 1996:1-8.
3. Bleicher JN, Hamiel S, Gengler JS. A survey of facial paralysis: etiology and incidence. *Ear Nose Throat J*. 1996;75:355-358.
4. Isse NG. Endoscopic facial rejuvenation: endoforehead, the functional lift. *Aesthetic Plast Surg*. 1994;18:21-25.
5. Clark RP, Berris CE. Botulinum toxin: a treatment for facial asymmetry caused by facial nerve paralysis. *Plast Reconstr Surg*. 1989;84:353-355.
6. Puig CM, Laferriere KA. A retrospective comparison of open and endoscopic brow-lifts. *Arch Facial Plast Surg*. 2002;4:221-225.
7. Kaye BL. The forehead-lift: a useful adjunct to facelift and blepharoplasty. *Plast Reconstr Surg*. 1977;60:161-171.
8. Daniel RK, Tirkkanits B. Endoscopic forehead-lift: an operative technique. *Plast Reconstr Surg*. 1996;98:1148-1157.
9. Ramirez OM. Endoscopic full facelift. *Aesthetic Plast Surg*. 1994;18:363-371.
10. Chasan PE, Kupfer DM. Direct K-wire fixation technique during endoscopic brow lift. *Aesthetic Plast Surg*. 1998;22:338-340.
11. Lorenc ZP. Endoscopic forehead-lift using screw fixation. *Aesthetic Surg*. 1996;16:19-22.
12. McKinney P, Illiana S. An accurate technique for fixation in endoscopic brow lift: a 5 year follow-up. *Plast Reconstr Surg*. 2001;108:1808-1810.
13. Landecker A, Buck J, Grotting J. A new resorbable tack fixation technique for endoscopic brow lifts. *Plast Reconstr Surg*. 2003;111:880-886.
14. Costantino PD, Hiltzik DH, Moche J, Preminger A. Minimally invasive brow suspension for facial paralysis. *Arch Facial Plast Surg*. 2003;5:171-174.
15. Moody FP, Losken A, Bostwick J, Trine FA, Eaves FF. Endoscopic frontal branch neurectomy, corrugator myectomy, and brow lift for forehead asymmetry after facial nerve palsy. *Plast Reconstr Surg*. 2001;108:218-224.
16. Takushima A, Harii K, Sugawara Y, Asato H. Anthropometric measurements of the endoscopic brow lift in the treatment of facial paralysis. *Plast Reconstr Surg*. 2003;111:2157-2165.
17. Rautio J, Pignatti M. Endoscopic forehead-lift for ptosis of the brow caused by facial paralysis. *Scand J Plast Reconstr Surg Hand Surg*. 2001;35:51-56.