

# Titanium Mesh and Hydroxyapatite Cement Cranioplasty: A Report of 20 Cases

*Yadranko Ducic, MD, FRCS(C)\**

**Purpose:** This article describes the use of titanium mesh and hydroxyapatite cement constructs for the treatment of large through-and-through calvarial defects.

**Patients and Methods:** Twenty consecutive calvarial defects (10 to 156 cm<sup>2</sup>) that resulted from surgical removal of neoplasms or were secondary to trauma were reviewed retrospectively after reconstruction with titanium mesh and hydroxyapatite cement. All patients were followed up by clinical examination and periodic radiographic studies for a minimum of 6 months (range, 6 months to 3 years). Three patients underwent biopsy of the construct at various points during their follow-up.

**Results:** There was no evidence of adverse healing, wound infection, or implant exposure or extrusion in any of the patients reviewed. Adequate 3-dimensional aesthetic restoration of calvarial contour was noted in each case. There was evidence of osseous ingrowth into the titanium mesh and hydroxyapatite cement construct in all 3 patients who underwent biopsy.

**Conclusion:** Titanium mesh and hydroxyapatite cement cranioplasty appears to be a reasonable method for the reconstruction of significant calvarial defects.

© 2002 American Association of Oral and Maxillofacial Surgeons  
*J Oral Maxillofac Surg* 60:272-276, 2002

Pathologic alteration in the shape of the calvarium may be caused by a number of processes, including traumatic defects, congenital lesions, and iatrogenic injuries. The use of cranioplasty, or calvarial reconstruction, after such alterations dates to ancient Peru (2000 BC), when a gold plate was first used to camouflage a frontal defect produced as a consequence of trephination.<sup>1</sup> Since that time, a variety of autografts and alloplasts have been used with varying success rates. Rib grafts, first described as a cranioplastic material by Dobrotowski,<sup>2</sup> and calvarial bone grafts, first reported by Muller,<sup>3</sup> have been the workhorses of calvarial reconstruction. We prefer the use of autologous calvarial and rib grafts in the reconstruction of the developing pediatric cranium. The ability of these

grafts to become integrated over time, with subsequent growth in keeping with the overall growth of the pediatric maxillofacial skeleton, makes this the material of choice in this age group.<sup>4,5</sup> In addition, calvarial bone grafts in this age group are fairly malleable, allowing reconstructive surgeons to reproduce the precise contour of the calvarium with relative ease. This is not the case in the adult who presents for calvarial reconstruction, in whom 1) subsequent growth and the necessity of the reconstruction to remodel over time and 2) the poor compliance of adult calvarial bone grafts make this a more difficult surgical option to accomplish with reliably rewarding outcomes. Correction of large calvarial defects with autografts may also be quite time consuming. Thus, a number of osseous alternatives have been proposed over time, including microvascular free tissue transfer and pedicled calvarium-bearing flaps.<sup>6</sup> In large part due to the technical expertise required and the varying outcomes associated with their use, these techniques have not been widely applied.

As a result of the difficulties in the use of autografts in adults, there has been an impetus for the development and application of a number of alloplastic alternatives in cranioplasty. Gold and silver in their pure forms were used widely in World War I but were subsequently abandoned because of their relative soft-

---

\*Assistant Professor, Department of Otolaryngology, University of Texas Southwestern Medical Center, Dallas, TX, and Chief, Division of Otolaryngology and Facial Plastic Surgery, John Peter Smith Hospital, Fort Worth, TX.

No financial or material support was provided by Stryker-Leibinger for this study.

Address correspondence and reprint requests to Dr Ducic: 1500 S Main St, Fort Worth, TX 76104; e-mail: yducic@aol.com

© 2002 American Association of Oral and Maxillofacial Surgeons

0278-2391/02/6003-0006\$35.00/0

doi:10.1053/joms.2002.30575

ness and inability to withstand even minor trauma. Advancements in metallurgy led to the development of a number of alloys that were associated with increased strength and less corrosion than pure metals. Vitallium (composed of cobalt, chromium, and molybdenum) was suitably inert and stable; however, lack of malleability and difficulty with intraoperative adjustments in shape led to its abandonment after successful initial use.<sup>7</sup> Tantalum and its less expensive alternative, stainless steel, were both in large part abandoned secondary to their radiopacity and their high heat and cold conduction, which led to intolerance of changes in the weather.<sup>8,9</sup> Thus, interest increased in the application of a number of acrylic resins, which were associated with improved malleability and radiolucency.

Methylmethacrylate, which permits simple and expeditious closure of calvarial defects, has continued to be the most widely applied alloplast in use today.<sup>10</sup> Unfortunately, late plate exposure, plate fracture, secondary infection, and alloplast displacement due to lack of incorporation at the donor site continue to be problems associated with the use of this material in cranioplasty.

The ideal substitute would be biocompatible, strong, lightweight, initially malleable, nonmagnetic, and easily secured and would have long-term stability. The ability of such a material to be integrated into the recipient site by osseous ingrowth would also be desirable. This article reviews our favorable experience in cranioplasty with the use of titanium mesh impregnated with hydroxyapatite cement.

## Materials and Methods

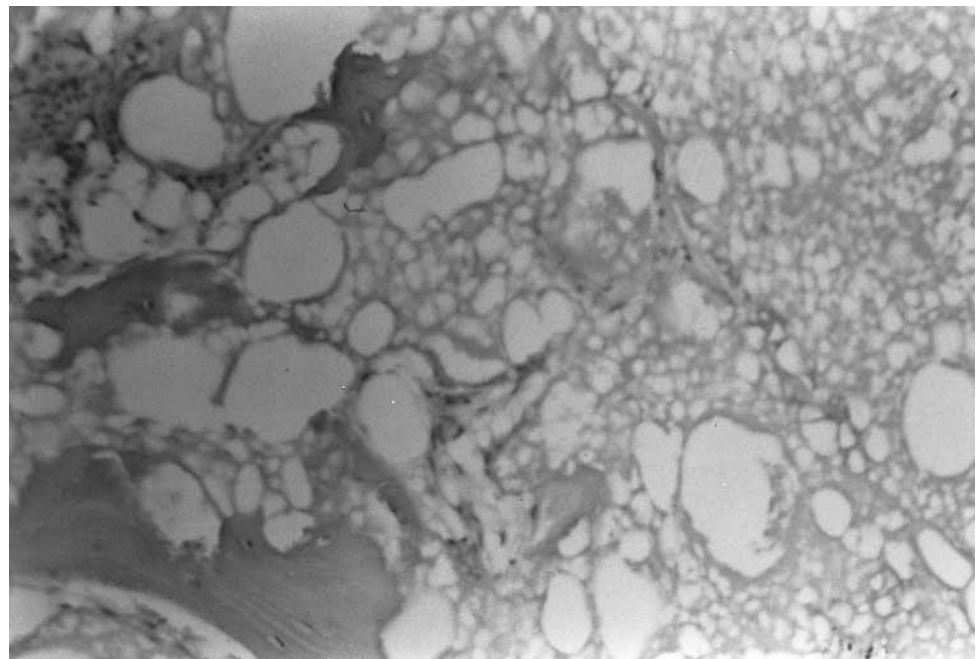
### TECHNIQUE

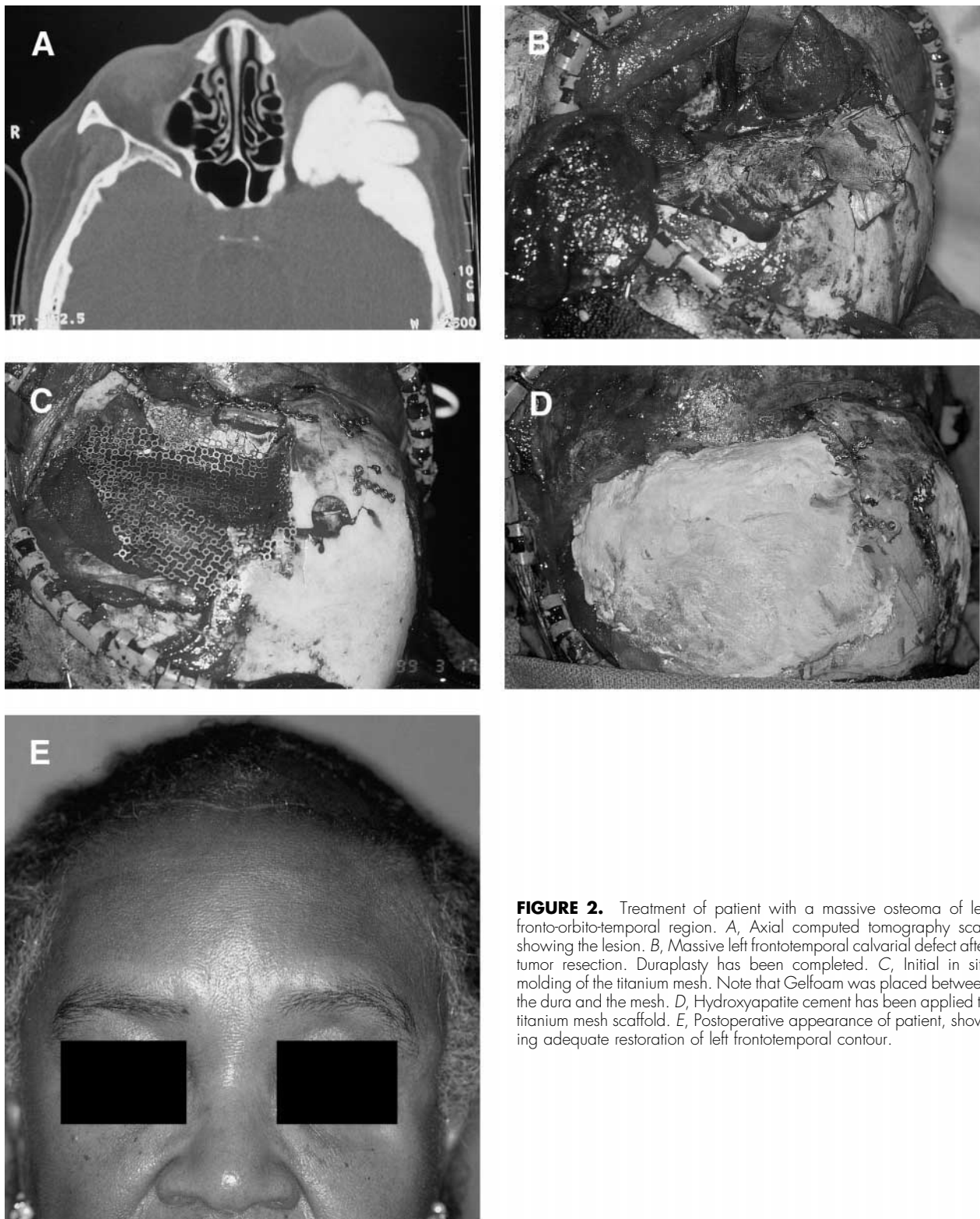
After coronal flap exposure of the surgical site in a subpericranial fashion, the region that requires cranioplasty is prepared. Any dural dehiscence or loss is first repaired, grafted if required, and, finally, sealed with fibrin glue or an equivalent. At this point, 2.0-mm Leibinger dynamic titanium mesh (Stryker-Leibinger, Kalamazoo, MI) is trimmed to a size that overlaps the edges of the calvarial defect by 0.5 to 1.0 cm circumferentially. The precise 3-dimensional contour is next achieved through digital manipulation of the mesh until the desired shape is reached. Then, a layer of Gelfoam (Upjohn, Kalamazoo, MI) is applied to the dura beneath the titanium mesh scaffold, which was rigidly fixed in situ with a series of titanium screws. Next, hydroxyapatite cement (Bonesource; Stryker-Leibinger) is placed in the titanium scaffold, completely covering it. The completed construct is allowed to set for a full 20 minutes before scalp closure over bulb drains. The patients are kept on a first-generation cephalosporin and metronidazole for 10 days after surgery.

### Results

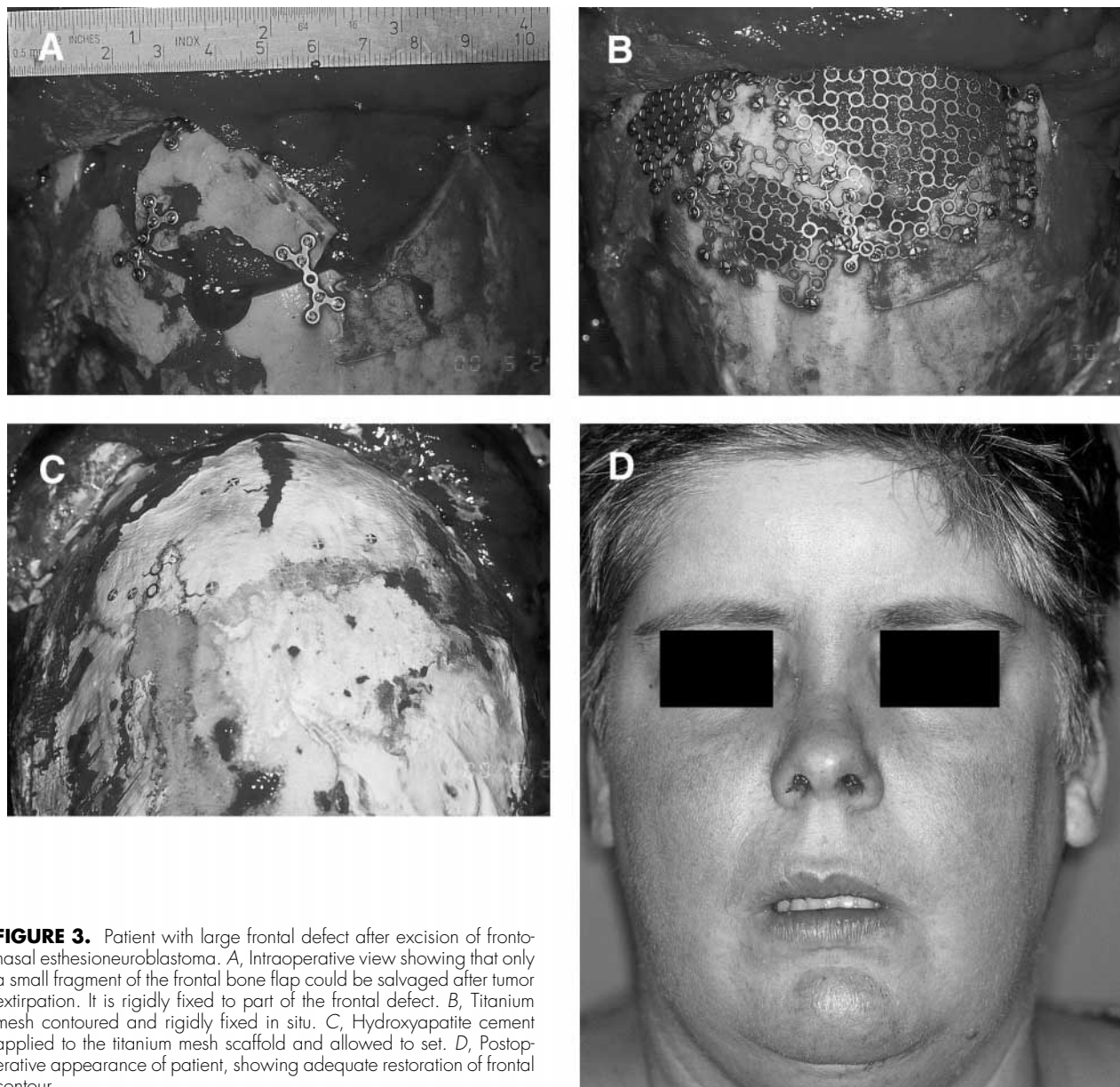
Twenty patients were treated with titanium mesh/hydroxyapatite cement cranioplasty over a period of 3 years. There was a minimum follow-up period of 6 months in each case. The primary location of the reconstruction included the frontal region (n = 12), the temporal region (n = 5), the parietal region (n =

**FIGURE 1.** Postoperative biopsy of titanium mesh/hydroxyapatite cement construct performed at 12 months demonstrating early osseous ingrowth into the hydroxyapatite cement (hematoxylin-eosin stain, original magnification  $\times 20$ ).





**FIGURE 2.** Treatment of patient with a massive osteoma of left fronto-orbito-temporal region. *A*, Axial computed tomography scan showing the lesion. *B*, Massive left frontotemporal calvarial defect after tumor resection. Duraplasty has been completed. *C*, Initial in situ molding of the titanium mesh. Note that Gelfoam was placed between the dura and the mesh. *D*, Hydroxyapatite cement has been applied to titanium mesh scaffold. *E*, Postoperative appearance of patient, showing adequate restoration of left frontotemporal contour.



**FIGURE 3.** Patient with large frontal defect after excision of fronto-nasal esthesioneuroblastoma. *A*, Intraoperative view showing that only a small fragment of the frontal bone flap could be salvaged after tumor extirpation. It is rigidly fixed to part of the frontal defect. *B*, Titanium mesh contoured and rigidly fixed in situ. *C*, Hydroxyapatite cement applied to the titanium mesh scaffold and allowed to set. *D*, Postoperative appearance of patient, showing adequate restoration of frontal contour.

2), and the occipital region ( $n = 1$ ). The size encompassed by the cranioplasty varied from 10 to 156 cm<sup>2</sup>. There was no evidence of implant infection, exposure, or extrusion in any of the patients. The construct appeared to be structurally stable over time in all patients. Three patients underwent biopsy of the construct at different times in the postoperative period (range, 1 to 2.5 years). Osseous ingrowth into the complex, with gradual replacement of the hydroxyapatite cement, was noted in each of the patients who underwent a biopsy (Fig 1). Figures 2 and 3 show examples of patients treated with this technique.

## Discussion

Hydroxyapatite cement consists of a calcium phosphate compound in a hexagonal structure. It bonds

well with in vivo bone and allows for osseous ingrowth over time.<sup>11</sup> Because it is a synthetic duplicate of a mineral that naturally occurs in bones and teeth, there is virtually no foreign body reaction noted on implantation. It has been used alone in cranioplasty for the treatment of relatively small calvarial defects.<sup>12</sup> Hydroxyapatite can be safely placed directly on dura. However, we prefer to cover the dura with a dry sheet of Gelfoam before cement application, because it facilitates graft removal or adjustment without the need to manipulate the dura.<sup>13</sup>

Our initial experience with hydroxyapatite cement indicated that it becomes quite brittle and has a low tensile strength when used without titanium mesh in major calvarial reconstruction. In addition, it is difficult to precisely adjust the 3-dimensional contour

without the underlying mesh in situ. The titanium serves as a stable scaffold for the hydroxyapatite cement, increasing the ability of the reconstruction to maintain its integrity over time. This situation is quite similar to the significantly improved outcomes associated with titanium mesh acting as a carrier for acrylic versus acrylic alone in cranioplasty.<sup>14</sup> An attempt to combine titanium mesh with bone dust in cranioplasty was not successful, because there appeared to be complete resorption of the bone dust in the long term, with virtually no evidence of new bone formation or ingrowth.<sup>15</sup> Each of the constructs in our series that underwent biopsy appeared to be stable over time and demonstrated conclusive evidence of osseous ingrowth.

Titanium is a nonferrous metal that is relatively radiolucent and causes no significant image degradation on either computed tomography or magnetic resonance imaging.<sup>16</sup> Furthermore, titanium is biocompatible and corrosion resistant and has a favorable modulus of elasticity that approximates that of in vivo bone more closely than other metals. Its ability to act as a stable scaffold for hydroxyapatite cement in weight-bearing portions of the maxillofacial skeleton has been previously reported.<sup>17</sup> In theory, because this construct appears to become slowly integrated over time with osseous ingrowth, one would expect it to have long-term biomechanical stability. However, none of the patients have experienced significant trauma to the construct after surgery, so its long-term impact resistance is not known.

Although no specific cost analysis has been attempted, the added cost of the hydroxyapatite cement and titanium mesh would be expected to be significantly offset by the time savings in the operating room compared with calvarial bone grafting and subsequent rigid fixation. In addition, there certainly is a patient benefit in terms of the lack of any potential donor site morbidity (rib and calvarial harvest sites).

We have had a favorable experience with this combination in major calvarial reconstruction. The

method is simple to teach and easy to apply and appears to be associated with functionally stable and aesthetically pleasing results when used in cranioplasty. This method appears to represent a useful alternative to autografts in the treatment of this patient population. Further long-term study of these patients would be useful to gauge the biologic sequelae, biomechanical stability, and impact resistance of this promising method of cranioplasty.

## References

1. Grana F, Rocca ED, Grana L: Las Trepanaciones Craneanas en el Peru en a Epoca Prehispanica. Lima, Peru, Imprenta Santa Maria, 1954
2. Dobrotowski WJ: Die rippen als material zur knochenautoplastik. *Zentralbl Chir* 32:1081, 1911
3. Muller W: Zur frage der tempoaren schadelresektion an stelle der trepanation. *Zentralbl Chir* 4:65, 1890
4. Derome P: Les tumeurs spheno-ethmoidales. *Neurochirurgie* 18:160, 1972
5. Weber RS, Kearns DB, Smith RJ: Split calvarium cranioplasty. *Arch Otolaryngol Head Neck Surg* 113:84, 1987
6. Bite U, Jackson IT, Wahner HW, et al: Vascularized skull bone graft in craniofacial surgery. *Ann Plast Surg* 19:3, 1987
7. Geib FW: Vitallium skull plates. *JAMA* 117:8, 1941
8. Woodhall B, Spurling RG: Tantalum cranioplasty for war wounds of the skull. *Ann Surg* 121:649, 1945
9. Scott M, Wycis H, Murtagh F: Long term evaluation of stainless steel cranioplasty. *Surg Gynecol Obstet* 115:453, 1962
10. Spence WT: Form fitting plastic cranioplasty. *J Neurosurg* 11: 219, 1954
11. Constantino PD, Friedman CD, Jones K, et al: Experimental hydroxyapatite cement cranioplasty. *Plast Reconstr Surg* 90: 174, 1992
12. Constantino PD, Chaplin JM, Wolpoe ME, et al: Applications of fast setting hydroxyapatite cement: Cranioplasty. *Otolaryngol Head Neck Surg* 3:409, 2000
13. Zide MF, Kent JN, Machado L: Hydroxylapatite cranioplasty directly over dura. *J Oral Maxillofac Surg* 45:481, 1987
14. Malis LI: Titanium mesh and acrylic cranioplasty. *Neurosurgery* 25:351, 1989
15. O'Broin ES, Morrin M, Breathnach E, et al: Titanium mesh and bone dust calvarial patch during cranioplasty. *Cleft Palate Craniofac J* 34:354, 1997
16. Chandler CL, Uttley D, Archer DJ, et al: Imaging after titanium cranioplasty. *Br J Neurosurg* 8:409, 1994
17. Ducic Y: Midface reconstruction with titanium mesh and hydroxyapatite cement: Report of a case. *J Craniomaxillofac Trauma* 3:35, 1997