



Liposuction of the face and neck

Robert DeFatta, MD, PhD, Yadranko Ducic, MD, MSc, FRCS(C), FACS

From the Center for Aesthetic Surgery, Colleyville, Texas.

KEYWORDS

Liposuction;
 Facelift;
 Necklift;
 Neck contour

Liposuction of the lower face and neck regions is a time-honored technique associated with aesthetically pleasing long-term results in the majority of patients. The keys to achieving an excellent outcome remain, as always, appropriate patient selection and proper execution. Modern ideals tend to favor more natural, blended results rather than the skeletonized appearance noted often in the past. Particular attention in the preoperative assessment must be directed at evaluation of the position of the hyoid bone and submandibular glands as well as the patient's overall body habitus. Concurrent rhytidectomy, neck lift or platysma plication may be required if significant skin laxity is present.

© 2007 Elsevier Inc. All rights reserved.

Increased fatty tissue deposition in the submental region, sagging jowls, and the redundancy of neck skin are all effects of aging and occur largely as a result of unavoidable mechanical strain placed by the forces of gravity. The jowl fat pads begin to sag below the inferior border of the mandible mainly as the result of increased skin laxity and, to a lesser extent, from laxity of the superficial musculoaponeurotic system (SMAS). These changes are evident in both the obese patient as well as patients with an appropriate body mass index.

It is important to note that younger patients also can present with poor neck esthetics, as evidenced by a prominent submental fat pad and a recessed chin. These changes are heritable and independent of aging. If left uncorrected, these poor neck esthetics will tend to further deteriorate with the addition of the normal aging process.

Another important point is that most individuals tend to gain weight as they age, and even a moderate weight gain will virtually always result in an increased prominence of the jowls and submental fat. Hence, most patients who desire esthetic improvement of the face and neck will benefit from liposuction of the neck and jowls.

Liposuction was introduced by an Italian father/son team of surgeons, Drs. Arpard and Giorgio Fischer, in 1975. They described a new method for the removal of unwanted fat deposits through the use of hollow needles under general anesthesia. The unprepared fat was fragmented by a motor-

ized cutting blade and removed via a suction machine they invented.¹ This procedure suffered from high intraoperative risks such as severe blood loss and poor esthetic results as well as a high rate of postoperative complications.

Shortly thereafter, Yves-Gerard Illouz, a Frenchman with a specialty in obstetrics and gynecology, pioneered the "wet technique." To facilitate aspiration of the adipose tis-

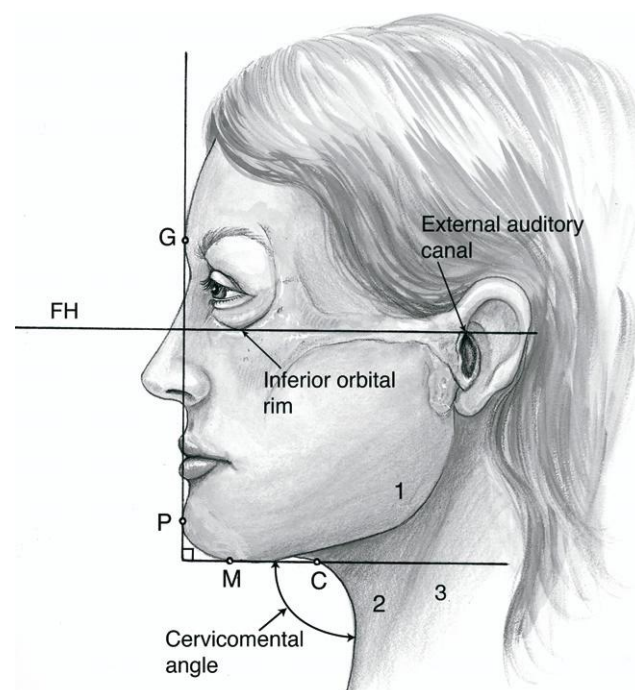


Figure 1 Preoperative analysis of the aging neck.

Address reprint requests and correspondence: Yadranko Ducic, MD, MSc, FRCS(C), FACS, Center for Aesthetic Surgery, 75 Main Street, Suite 150, Colleyville, TX 76034.

E-mail address: yducic@sbcglobal.net.

sue and reduce blood loss, he injected hypotonic saline and hyaluronic acid into the fat before liposuctioning.² Dr. Illouz' other significant contribution was the introduction of the blunt canula to improve the safety profile of liposuction.

The advent of liposuction spread worldwide, with the first case being performed in the United States in 1982 by Martin, a Los Angeles Otolaryngologist. In 1987, Jeffrey Klein, a dermatologist from California described the tumescent technique, a combination of the wet technique and a local anesthetic procedure.³ By instilling large volumes of physiologic saline (tumesce = to swell) with lidocaine for local anesthesia, he revolutionized liposuction via minimizing the operative and anesthetic risks and transformed liposuction into an outpatient procedure.

Lipectomy of the neck has been described as far back as 1968⁴; however, the modification of liposuction was not

introduced until 1984.⁵⁻⁷ This article describes both the preoperative evaluation and operative technique that, when applied, will lead to reproducible results.

Preoperative evaluation

Appropriate candidate selection is essential to obtaining good postoperative results. The profile view allows for the best evaluation of a patient's neck. With the patient's head in the Frankfort horizontal plane, one can determine the cervicomental angle, the most important cephalometric parameter that illustrates the youthful neck (Figure 1). This angle is defined by the intersection of the vertical anterior facial plane and the submental plane. Patients with ideal neck proportions have cervicomental angles between 90 and

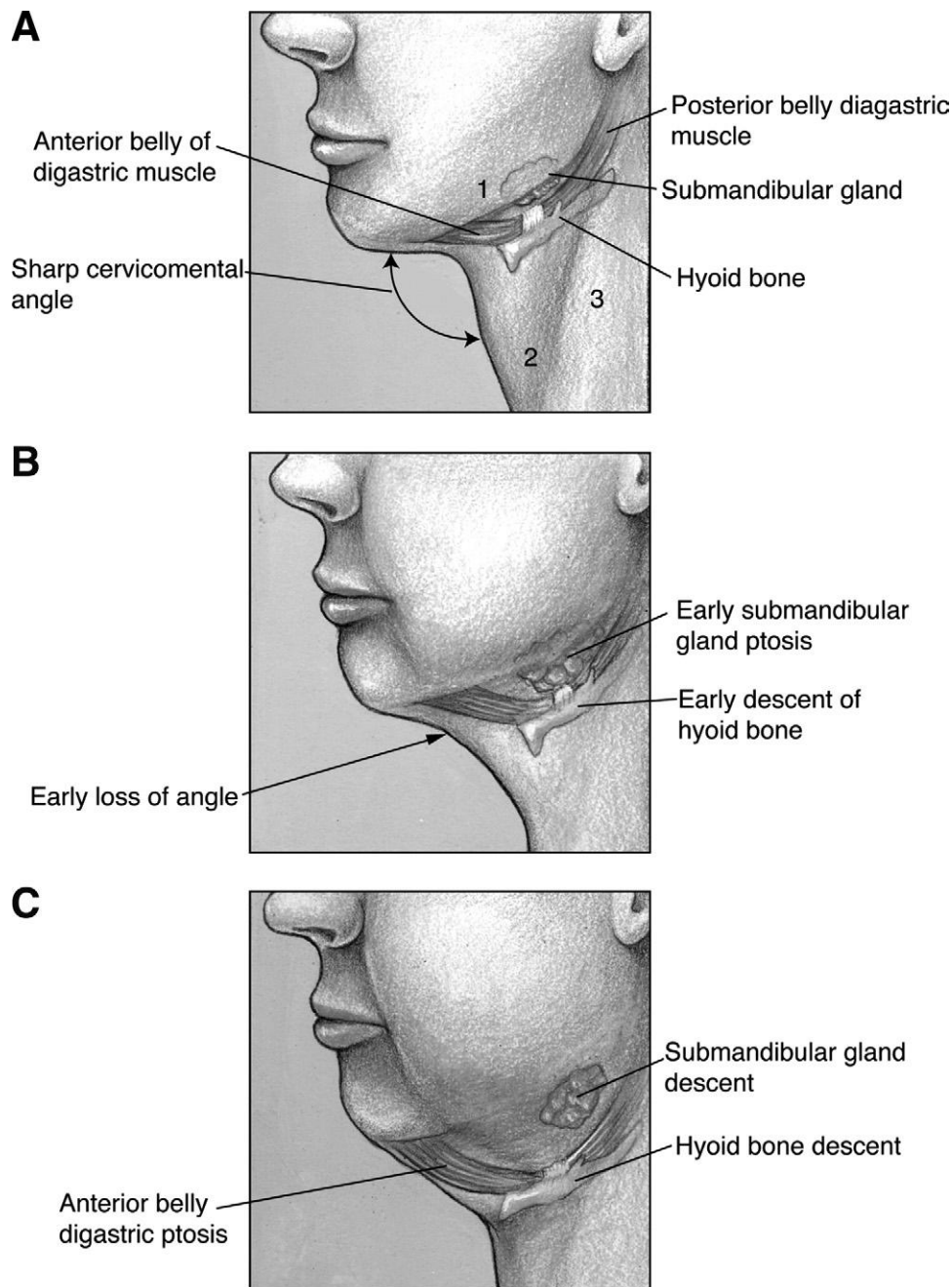


Figure 2 Changes in cervicomental angle with aging. (A) Youthful patient with sharp cervicomental angle. (B) Early stage of aging process. (C) Late stage of aging process.

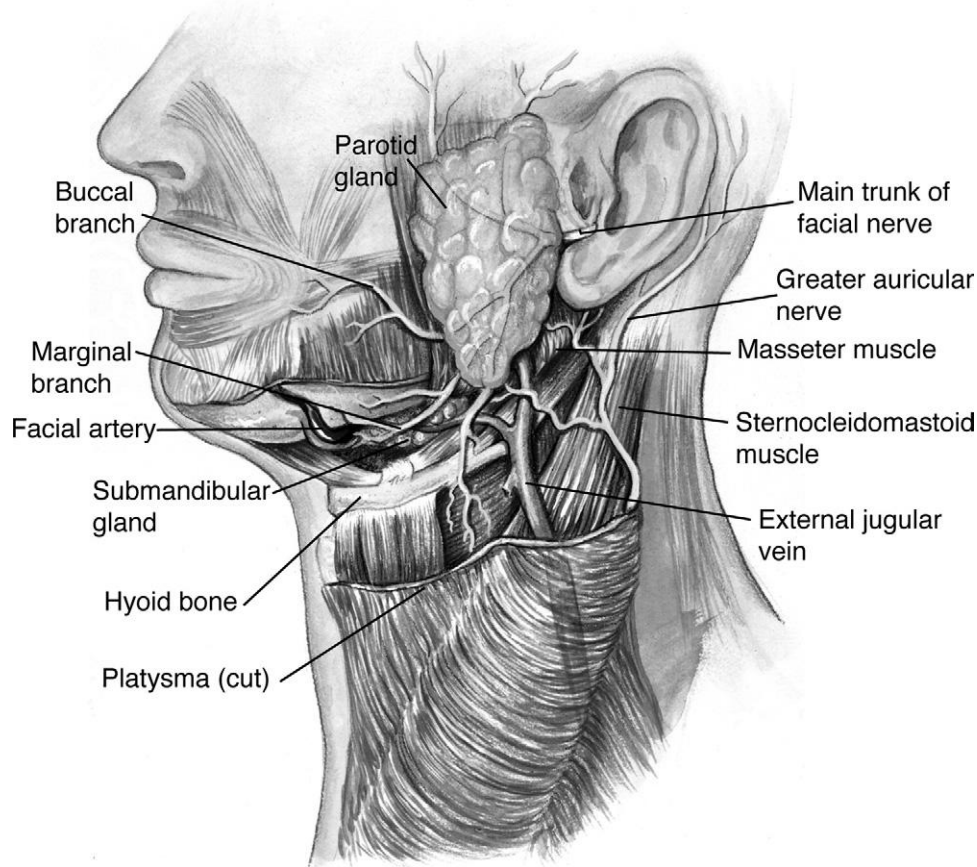


Figure 3 Key anatomic landmarks in the neck.

120°. Other criteria that are correlated to a youthful neck include a well-defined lower mandibular border, a slight bulge produced by the thyroid cartilage, a visible anterior border of the sternocleidomastoid muscle, and a sharp submental-cervical angle (Figure 2A).

With age, gravitational changes, and increased adipose deposition, there is an increased cervicomenal angle and an obliteration of the youthful neck esthetic features (Figure 2B). Also, as the superficial musculoaponeurotic system and skin in the submental region progressively increase their laxity, the chin will eventually become recessed which, in conjunction with an increase in adipose tissue, will give the neck a significantly aged appearance (Figure 2C).

Two other important structural features to evaluate are the location of the submandibular glands and the hyoid bone. The ideal position of the hyoid is at the C3–C4 level, which correlates to a position at or higher than the menton. Patients with a low-set hyoid are less likely to achieve a sharp cervicomenal angle because of the displaced location of the anterior belly of the digastric muscle. As it is pulled downward with the hyoid, it will prevent the establishment of a sharp cervicomenal angle. It is also important to determine whether a patient's jowls are solely from an excess of adipose tissue deposition or whether a ptotic submandibular gland is also contributing to the problem. If the latter is the case, one will not be able to achieve a sharp angle at the inferior border of mandible unless the gland is repositioned superiorly.

The platysma muscle is one of the most important structures in the neck when discussing liposuction. It is this

muscle layer that separates the subcutaneous neck fat from the underlying structures (Figure 3). It is important to note that the platysma is thin and can be easily penetrated with a liposuction cannula. The marginal mandibular nerve, the

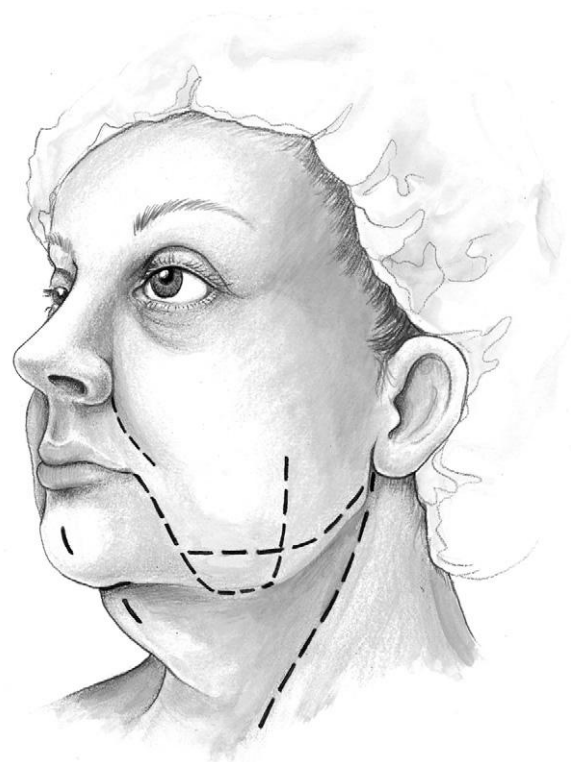

Figure 4 Preoperative marking of the patient.

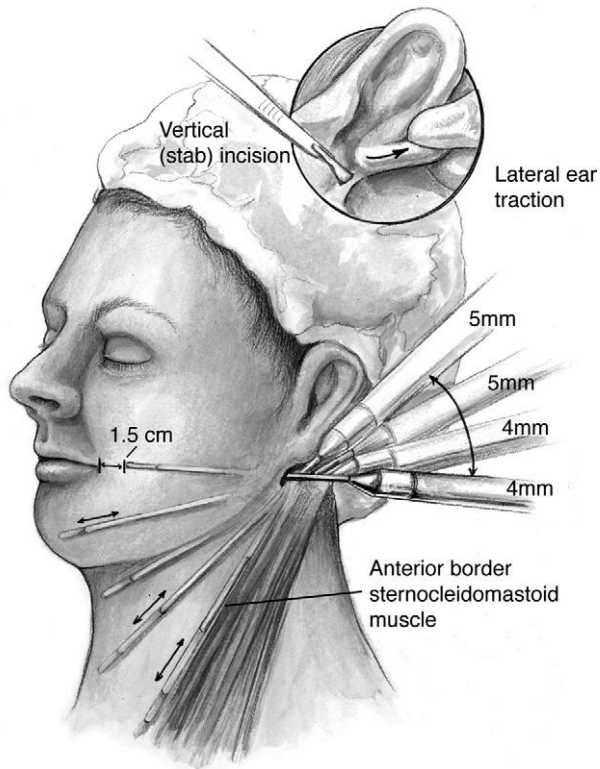


Figure 5 Neck liposuction through auricular incision.

most injured structure during liposuction of the neck, has a variable course to its final innervation at the corner of the mouth. At its most caudal point, it can be anywhere from above the inferior edge of the mandible to the inferior edge of the submandibular gland. Another important structure is the external jugular vein and the greater auricular nerve,

both of which course superficial to the sternocleidomastoid muscle (SCM).

Technique

The patient should be marked while he or she is looking straight ahead in either the sitting or standing position preoperatively. The patient's submental crease, inferior border of the mandible, anterior border of the SCM, and the jowls are then noted (Figure 4). The anterior jowl border, or the "marionette line," extends from the oral commissure to the inferior edge of the mandible. The posterior and inferior borders are determined by pinching the skin, which allows one to palpate the thickness of the subcutaneous fat pad.

Once the patient has been placed on the operating table in the supine position, a #15 blade is used to make a total of 3 stab incisions. The first incision is made on the attachment of the auricular lobule to the neck. Once this has been repeated on the other ear, the third and final stab incision is made in the midline at the submental crease. Once the incisions have been made, the tumescent solution is infused using a 2-mm multiport canula attached to a 20-mL syringe. From the auricular incision, the tumescent solution is injected starting in a direct line to the oral commissure, but stopping 1.5 cm from the lips, and injected in a sequential fashion in a caudal manner onto the neck until the anterior border of the SCM is reached. Once this has been performed through both lobular incisions, the submental crease incision is used to inject from the anterior border of the SCM on one side of the face to the contralateral anterior SCM bor-

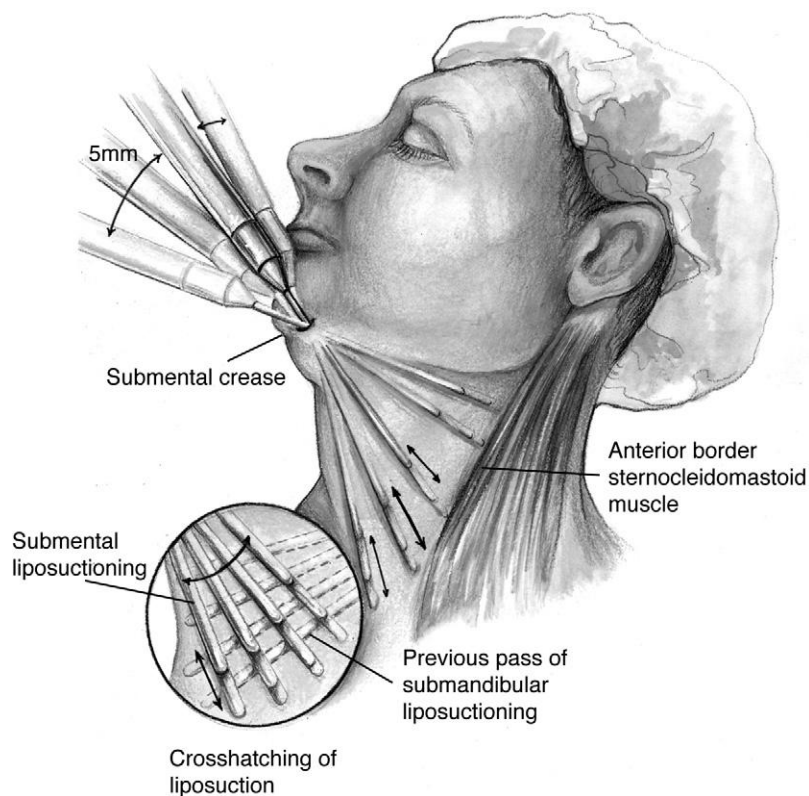


Figure 6 Neck liposuction through submental incision.

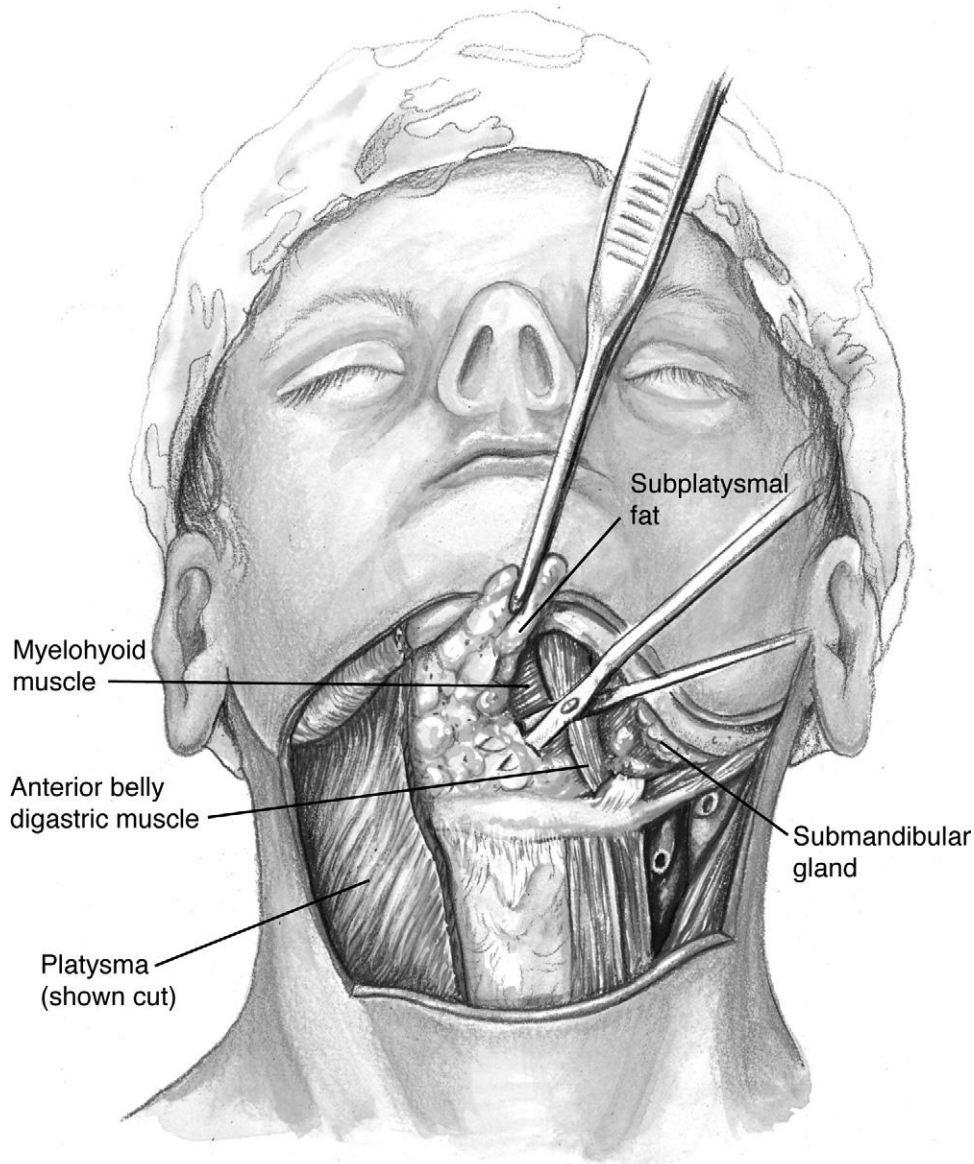


Figure 7 Subplatysmal fat resection.

der. A total of 75–100 mL of tumescent solution is injected and allowed to diffuse through the subcutaneous fat for a total of 10 minutes.

The lateral neck is first suctioned by attaching a 10-mL syringe onto a 4-mm blunt canula that contains a single side opening for removal of fat (Figure 5). Once the canula has been introduced into the auricular incision, sequential radial passes are made from as high as the oral commissure to just below the inferior border of the mandible. The suction opening should always face away from the skin surface to prevent dimpling of the neck. As previously stated, the canula is stopped 1.5 cm from the oral commissure. Next, a 5-mm, single-opening, blunt tip canula is used to suction the neck. The direction of liposuction progresses in a cranial to caudal fashion. The canula can be passed just across midline and as far lateral as the anterior border of the SCM. By starting on the face and continuing onto the neck, one can feather the suctioning of the fat, which prevents the formation of a distinct transition zone between the neck and the face at the inferior border of the mandible while still allowing for removal of a significant amount of subcutaneous fat

from the lower face (Figure 6). By performing the liposuction in a crisscross fashion, one can achieve a more uniform fat removal and prevent such complications as dimpling or asymmetric fat removal.

Some patients can have a significant subplatysmal fat component in the submental area. If this is the case, after liposuctioning has been performed, the stab incision that was previously made in the submental crease can be increased to a total of 1.5 cm. This increase will allow access to the subplatysmal fat and can be removed through direct visualization (Figure 7). If there is a significant dehiscence of the platysma, platysma plication can be performed to help achieve a more esthetic neck appearance.

The submental and lobular incisions are then closed with interrupted 6.0 fast absorbing gut sutures. Next, a compressive dressing is placed over the neck and left in place for a total of 3 days to promote even adherence of skin to the underlying tissues and to decrease the risk of hematoma formation. When the dressing is removed in 3 days, most of the swelling will have subsided and patients will be able to see a substantial improvement com-

pared with their preoperative state. A jaw bra is then worn nightly for 3 weeks.

References

1. Fischer A, Fischer G: Revised technique for cellulitis fat reduction in riding breeches deformity. *Bull Int Acad Cosmetic Surg* 2:40-41, 1977
2. Illouz Y: Body contouring by lipolysis: A 5-year experience with over 3000 cases. *Plast Reconstr Surg* 72:511-524, 1983
3. Klein JA: The tumescent technique for liposuction surgery. *Am J Cosmetic Surg* 4:236-267, 1987
4. Millard DR, Pigott RW, Hedo A: Submandibular lipectomy. *Plast Reconstr Surg* 41:513-522, 1968
5. Martin N: Liposuction for the double chin, in Ward PH, Berman WE (eds): *Plastic and Reconstructive Surgery of the Head and Neck*, vol 1. St. Louis, MO, The CV Mosby Co, 1984, pp 383-389
6. Elam MV, Berkowitz F: Liposuction: a method of submental and facial defatting, in Ward PH, Berman WE (eds): *Plastic and Reconstructive Surgery of the Head and Neck*, vol 1. St. Louis, MO, The CV Mosby Co, 1984, pp 390-396
7. Newman J, Dolsky RL, Mai ST: Neck sculpturing by liposuction extraction, in Ward PH, Berman WE (eds): *Plastic and Reconstructive Surgery of the Head and Neck*, vol 1. St. Louis, MO, The CV Mosby Co, 1984, pp 397-407