

---

ROBERT M. KELLMAN, MD, FACS  
SHERARD A. TATUM III, MD, FAAP, FACS  
LAWRENCE J. MARENTETTE, MD, FACS, GUEST EDITORS

---

# FACIAL PLASTIC SURGERY CLINICS of North America

Facial Trauma: Primary and Secondary Repair

---

NOVEMBER

1 9 9 8

---

## FRACTURES OF THE MIDFACE

Yadranko Ducic, MD, FRCS(C),  
and David Duffield Hamlar, MD, DDS

Fractures of the maxilla are relatively common, comprising approximately 15% to 20% of all fractures of the maxillofacial region.<sup>13, 14</sup> The vast majority are noted to occur in the young adult male population (male:female ratio of 5:1), predominantly as a sequela of injury sustained in motor vehicle accidents, assaults, and falls.<sup>29</sup> The overall incidence of these injuries has significantly decreased with the more routine availability of air bags, shoulder seat belt restraints, and collapsible dashboards and steering columns.

These fractures are of significant functional, as well as esthetic, importance. In the healthy individual, the maxilla forms a solid, incompletely pneumatized bone that serves to bridge the upper (frontoethmoid region and skull base) and lower (occlusal plane) parts of the craniomaxillofacial skeleton. Consequently, traumatic disruption of this bridge leads not only to the classic loss of midfacial height seen in these patients, but also to pathologic alteration of the numerous structures of functional significance in the area. Thus, disorders of occlusion, nasal breathing, lacrimation, and facial sensation are frequently found in patients suffering from fractures of the maxilla. Similarly, the malar eminence represents a key esthetic highlight of the face, contributing to facial width, projection, and the bony contour of the orbit. As a result of its intimate relationship with the orbit and mandible, ophthalmologic

findings and malocclusion may also be noted in these patients.

Before the era of precise rigid internal fixation of facial fractures, long-term morbidity resulting from fractures of the midface was a significant problem. Fixation of these fractures with closed reduction or nonrigid fixation techniques often allowed for migration and malrotation of the fractured segments, potentially resulting in poor patient outcomes. Now, good exposure and knowledgeable application of rigid internal fixation devices, based upon sound principles, predictably results in favorable outcomes for the majority of these patients.

### ANATOMIC CONSIDERATIONS

The maxilla is composed of a body, which houses the variably pneumatized maxillary antrum, and four processes: (1) the zygomatic, (2) frontal, (3) palatine, and (4) alveolar. Nahun<sup>24</sup> studied the magnitude of force required to elicit fractures experimentally in the human maxillofacial skeleton. The conclusions of this trial revealed that the force required to generate a fracture of the midface was relatively low in comparison with most other facial bones. In fact, the bony integrity of the midface was generally disrupted with only one third the force necessary to fracture the mandible and one fifth the force required to produce a frac-

---

From the Division of Otolaryngology and Facial Plastic Surgery, John Peter Smith Hospital, Fort Worth, Texas (YD); and the Department of Otolaryngology at Regions Hospital, Saint Paul, Minnesota (DDH)

ture of the frontal sinus area.<sup>24</sup> From the standpoint of self-preservation, the ability of the midface to fracture with relative ease allows it to function as a midfacial "shock-absorber," significantly decreasing the amount of force allowed to progress posteriorly to the central nervous system and eye.

The key to understanding fractures of the midface is the realization that the maxilla is maintained in normal anatomic position, between the mandible and the skull base, by a series of four supporting pillars, commonly referred to as *vertical buttresses* (Fig. 1). These buttresses represent the load paths for the distribution of the powerful vertical forces of mastication. In the human maxillofacial skeleton, there are three paired buttresses: (1) the nasomaxillary, (2) the zygomaticomaxillary, and (3) the pterygomaxillary; and a single midline buttress, the nasoseptum (vomer, crista galli, perpendicular plate of the ethmoid bone and the cartilaginous septum). The nasomaxillary (medial) buttress extends from the dentoalveolar arch in the region of the canine, along the pyriform aperture, and ends at the medial orbital rim and frontomaxillary suture; the zygomaticomaxillary (lateral) buttress arises from the region of the maxillary first molar,

and runs superiorly through the body of the zygoma to terminate at the lateral wall of the orbit and the frontozygomatic suture; the pterygomaxillary (posterior) buttress runs from the maxillary tuberosity, through the pyramidal process of the palatine bone and the medial plate of the pterygoid bone, to end at the basisphenoid.<sup>21</sup> The alveolus, hard palate, inferior orbital rim, and frontal bar constitute the primary horizontal supports (or horizontal buttresses) that serve as a foundation for the vertical buttresses. The alveolar process of the maxilla is dependent on the presence of the patient's native dentition to maintain its structural integrity. Edentulousness is, thus, accompanied by alveolar atrophy. This results in a generalized weakening of the support it can provide for the midface, leading to an increased predisposition to traumatic disruption.

The midface attachment to the basisphenoid is normally angulated at approximately 45 degrees. Traumatic breakdown of the buttresses leads to a relative release of the maxilla from its bony attachments. This allows the medial and lateral pterygoid muscles, attached to the posterolateral aspect of the maxilla at the level of the pterygoid plates, to pull the fractured maxilla posteroinferiorly along the skull base

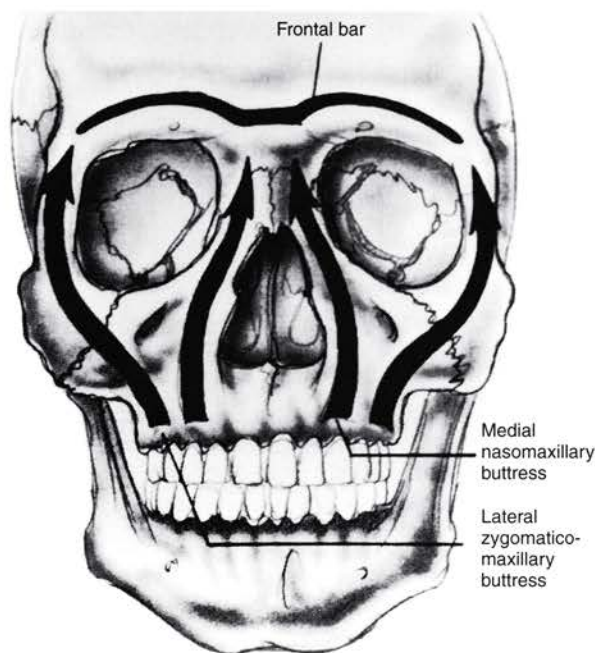


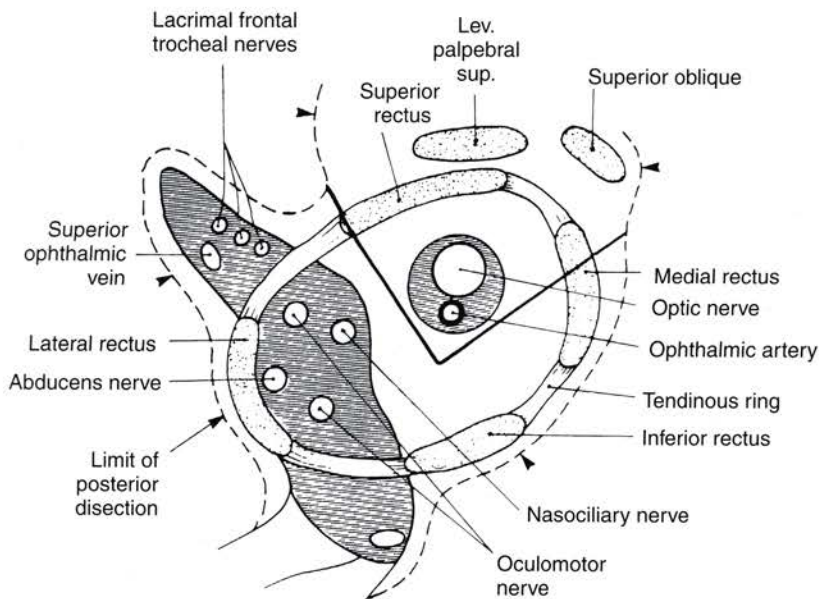
Figure 1. The midfacial buttress system.

(altering the normal 45-degree angulation), leading to the classic anterior open bite deformity noted in these patients.

The zygomatic bone is generally considered to consist of a central zygomatic or malar body, from which extend three distinct processes: (1) temporal, (2) orbital, and (3) maxillary. The body of the zygoma represents the strongest portion of the zygomatic complex. It forms an important part of the lateral buttress. When this buttress is disrupted as part of a classic zygomatic complex fracture, one notes inferomedial rotation of the zygomatic bone. Although questioned by some, the masseter muscle seems to be the major force maintaining the displacement of a rotated zygomatic fracture.<sup>4</sup> The maxillary process of the zygoma articulates inferomedially with the maxilla, forming part of the anterolateral wall of the maxillary antrum. The temporal process articulation with the temporal bone results in the creation of the zygomatic arch, which is responsible for maintenance of the anterior projection of the malar eminence. The zygomatic arch is not curved in its entire extent. It is curved at its origins from the temporal bone and zygomatic body, but is flat in its central two thirds. The arch also serves as a point of attachment for the masseter muscle and the two leaves of the

deep temporal fascia. The frontal branch of the facial nerve is closely associated with the anterior aspect of the arch, following a course approximating a line drawn from the inferior aspect of the tragus to a point 1.5 to 2 cm above the lateral brow. Transection of this nerve results in poor esthetic outcomes caused by the lack of crossinnervation of the mimetic muscles of the forehead from adjacent branches of the facial nerve. The temporomandibular joint and coronoid process are situated deep to the arch. Thus, arch disruption may result in impingement or disruption of these structures, leading to masticatory problems.

The orbital process of the zygoma contributes to the formation of the floor of the orbit through its articulation with the orbital plate of the maxilla. The inferior orbital fissure divides the zygomatic and maxillary contributions to the orbital floor. In properly reducing noncomminuted fractures of the zygoma, an important indicator of the accuracy of the reduction is the articulation of the orbital process of the zygoma with the greater wing of the sphenoid within the lateral wall of the orbit (Fig. 2). Not surprisingly, up to 40% of patients with zygoma fractures involving the floor of the orbit have concomitant intraocular injury.<sup>16</sup>



**Figure 2.** Orbital apex anatomy familiarity is critical when approaching fractures of the orbital floor.

Knowledge of the neurovascular supply to the midface is, on occasion, critically important in allowing the surgeon to plan safe surgical approaches to its repair. At the junction of the hard and soft palates emerge the greater palatine nerve and artery, which supply all of the bone and mucosa of the hard palate. The posterior superior alveolar artery and nerve (branches of the maxillary artery and nerve) supply the molar teeth, whereas the anterior superior alveolar artery and nerve (branches of the infraorbital artery and nerve) supply the anterior teeth. Thus, fractures of the orbital floor or anterior aspect of the maxilla may result in paresthesia of the anterior teeth, whereas fractures of the posterior maxilla may give molar paresthesia. The maxilla also receives some blood supply from the gingival attachments to its alveolar process and, indirectly, via its soft palate attachments from the ascending pharyngeal and facial (pharyngeal and palatine branches) arteries. Generally, in trauma, one does not need to be overly concerned with the blood supply to the maxilla. In the case of major degloving of soft tissue and, especially, if there is concomitant release of the soft palate attachments to the maxilla, however, one needs to be very careful to try to preserve any remaining attachments during surgical exploration, lest it lead to maxillary devascularization. This may be quite detrimental in terms of subsequent healing and susceptibility to infection.

## CLASSIFICATION

In 1901, Le Fort<sup>19</sup> presented the results of the cadaveric experiments he had performed in an effort to determine whether or not there was a predictable pattern to midfacial fractures. These experiments consisted of striking supported and unsupported cadaver heads with a wooden club, or dropping them from a height of several stories onto the pavement in front of his research facility. Three classic fracture patterns emerged from these studies. Originally, Le Fort<sup>19</sup> described the three fracture levels as I, II, and III, with the Le Fort I representing craniofacial dysjunction, and Le Fort III representing supra-alveolar fracture. In common usage, the Le Fort classification associated with these two fracture levels has, for some reason, become reversed from his

original description (Fig. 3). Thus, Le Fort I fracture, which was in fact first described by Guerin in 1866, is a low transverse fracture crossing the maxilla (supra-alveolar and submalar course) and nasal septum, resulting in separation of the palate from the body of the maxilla.<sup>30</sup> The fracture line passes along the floor of the nose, pyriform aperture, canine fossa, and lateral wall of the maxilla. Le Fort I fractures, although usually not involving the pterygoid plates, may on occasion traverse their inferior aspect, most commonly at the junction of their upper two thirds and lower one third. The septum is often fractured at the level of the floor of the nose in Le Fort I fractures. Clinically, these fractures result in what is generally termed a *floating palate*.

The Le Fort II, or pyramidal fracture, crosses the nasal bones, descends steeply down the frontal process of the maxilla and lacrimal bone, and then crosses the orbital rim, being the only fracture of the maxilla to do so. The fracture line terminates by passing through the lateral wall of the body of the maxilla and into the pterygoid plates at the base of the skull. A high septal fracture is also usually noted with this fracture pattern. The clinical correlate of this fracture pattern is that of a *floating maxilla*.

The most severe fracture of the maxilla, the Le Fort III, results in *craniofacial dysjunction*. After fracturing the nasal bones and septum, the Le Fort III fracture line sequentially traverses the frontal process of the maxilla, lacrimal bone, lamina papyracea (and ethmoid air cell system), and orbital floor (posterior to the inferior orbital fissure) before bifurcating into two distinct limbs. One of these limbs extends across the lateral orbital wall, at the level of the sphenozygomatic junction, and often terminates by crossing the zygomatic arch. The second limb follows a more posterior course across the posterior aspect of the body of the maxilla, crossing into the infratemporal fossa, and ending by passing through the superior aspect of the pterygoid plates at the level of the basisphenoid. The fracture line often traverses the perpendicular plate of the ethmoid bone, with a consequently greater chance of sustaining dural tears and cerebrospinal fluid (CSF) leaks than with either the Le Fort I or II fracture patterns.

In his original description of fractures of the maxilla, Le Fort<sup>19</sup> acknowledged that his three great fracture lines often occurred in combina-

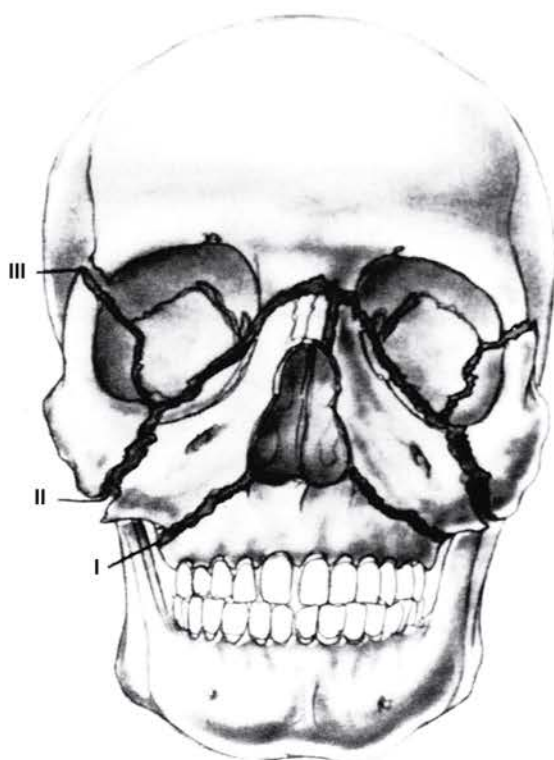


Figure 3. Classic Le Fort levels of midfacial fracture.

tion, and were often associated with any of a number of different nonclassified fracture lines. Thus, common nomenclature refers to pure Le Fort fractures, when the fracture lines follow Le Fort's classic description, and impure Le Fort fractures, when there are other fracture lines present or when there is incomplete separation across Le Fort's three lines of weakness. Furthermore, although Le Fort fractures are usually bilateral, they are commonly asymmetric between the two sides of the facial skeleton.

Le Fort's classification system provides the surgeon with a useful starting point from which to organize a valid treatment plan; however, it does not provide a full description of the degree of displacement or comminution that may be present. It also ignores other frequently noted fracture patterns, namely medial maxillary, palatal parasagittal, dentoalveolar, and anterior maxillary fractures. These are often referred to as *non-Le Fort fractures*.

Although numerous classification systems have been proposed for the description of zygomatic complex fractures, most are in-

adequate or impractical to be clinically useful.<sup>3,11,18</sup> The most widely accepted and clinically useful classification system continues, however, to remain the one proposed by Jackson.<sup>15</sup> He divided zygomatic fractures into four groups: (1) group 1—nondisplaced fractures, no treatment required; (2) group 2—localized segmental fractures, require exposure and direct fixation; (3) group 3—low-velocity injury causing displaced "tripod" fractures, require simple elevation or elevation, direct exposure, and rigid fixation; (4) group 4—high-velocity injury causing displaced comminuted fractures, require wide surgical exposure and rigid fixation at multiple points.<sup>15</sup> This is a clinically useful classification system that relates the pattern of injury and the magnitude of the force vector to a general approach to treatment.

Although fractures that result in full bony release of the body of the zygoma from the facial skeleton are generally referred to as "*tripod*" fractures, this is a misnomer. In fact, it is more aptly described as a quadripod fracture, because it entails disruption across the four articulation points of the zygoma. One of these

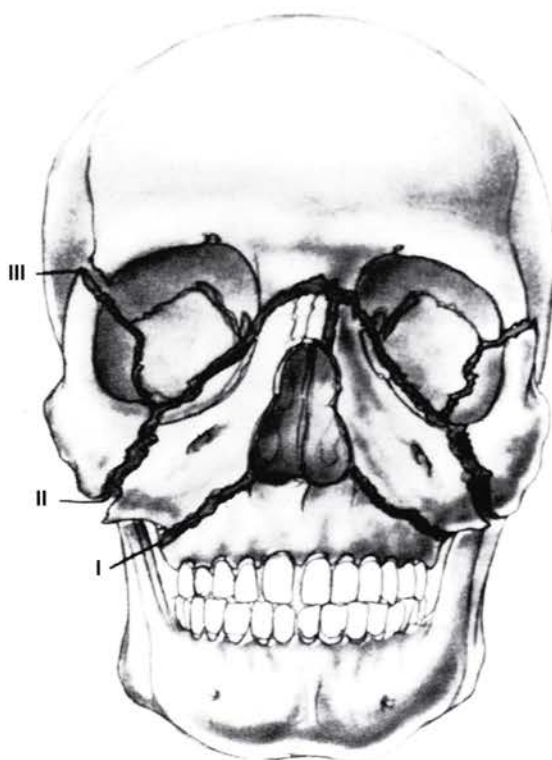


Figure 3. Classic Le Fort levels of midfacial fracture.

tion, and were often associated with any of a number of different nonclassified fracture lines. Thus, common nomenclature refers to pure Le Fort fractures, when the fracture lines follow Le Fort's classic description, and impure Le Fort fractures, when there are other fracture lines present or when there is incomplete separation across Le Fort's three lines of weakness. Furthermore, although Le Fort fractures are usually bilateral, they are commonly asymmetric between the two sides of the facial skeleton.

Le Fort's classification system provides the surgeon with a useful starting point from which to organize a valid treatment plan; however, it does not provide a full description of the degree of displacement or comminution that may be present. It also ignores other frequently noted fracture patterns, namely medial maxillary, palatal parasagittal, dentoalveolar, and anterior maxillary fractures. These are often referred to as *non-Le Fort fractures*.

Although numerous classification systems have been proposed for the description of zygomatic complex fractures, most are in-

adequate or impractical to be clinically useful.<sup>3,11,18</sup> The most widely accepted and clinically useful classification system continues, however, to remain the one proposed by Jackson.<sup>15</sup> He divided zygomatic fractures into four groups: (1) group 1—nondisplaced fractures, no treatment required; (2) group 2—localized segmental fractures, require exposure and direct fixation; (3) group 3—low-velocity injury causing displaced "tripod" fractures, require simple elevation or elevation, direct exposure, and rigid fixation; (4) group 4—high-velocity injury causing displaced comminuted fractures, require wide surgical exposure and rigid fixation at multiple points.<sup>15</sup> This is a clinically useful classification system that relates the pattern of injury and the magnitude of the force vector to a general approach to treatment.

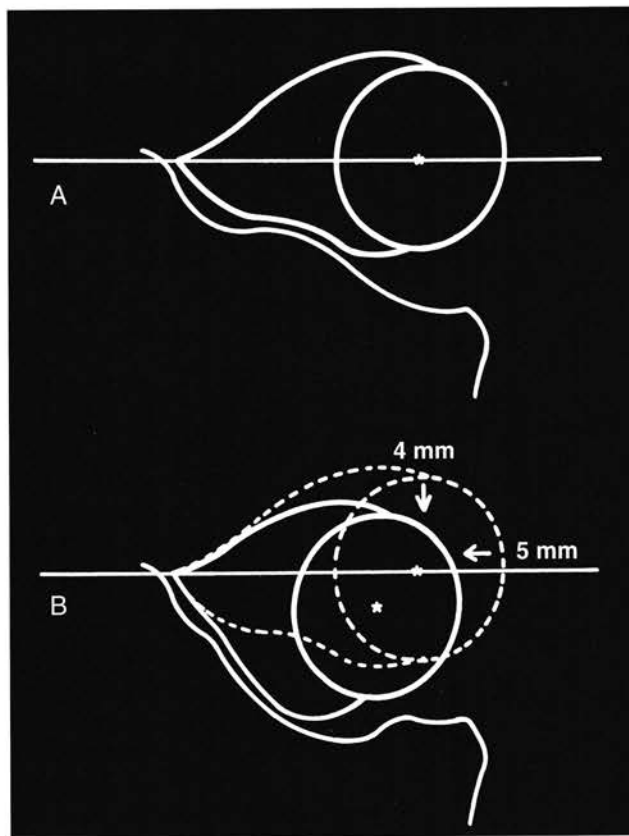
Although fractures that result in full bony release of the body of the zygoma from the facial skeleton are generally referred to as "*tripod*" fractures, this is a misnomer. In fact, it is more aptly described as a quadripod fracture, because it entails disruption across the four articulation points of the zygoma. One of these

points of disruption is the zygomaticomaxillary articulation at the level of the inferior orbital rim and orbital floor. Although fracture of the rim may or may not be associated with fracture of the orbital floor, an orbital floor component to the fracture is usually noted. The rim is most apt to fracture at its weakest point, overlying the area traversed by the infra-orbital nerve and just lateral to this area. With a greater application of force, disruption, and indeed, comminution, at several points along the rim can, of course, occur. The second level of disarticulation of the zygoma is the zygomaticofrontal suture and across the lateral orbital rim. The third level of fracture is at the zygomaticotemporal articulation. Subsequent disruption of the normal anatomic configuration of the zygomatic arch ranges from a greenstick-type alteration of the curve of the arch to complete segmental fracture or comminution. The final point of fracture is a low transmaxillary (across the zygomaticomaxillary buttress) disruption inferior to the body of the zygoma.

Associated orbital fractures may be divided into anterior and posterior segments based upon pathologic features and reconstructive requirements. The anterior segment may be viewed as consisting of the orbital rim and anterior aspects of the medial wall, roof, and floor. Defects in this area rarely compromise orbital volume and can be easily repaired. It must be remembered that anterior floor fractures can entrap the inferior rectus and inferior oblique muscles. On the other hand, the shape and volume of the posterior orbital cavity is critical to ocular projection. Small changes in this area due to traumatic disruption can cause profound affects (Fig. 4).

### CLINICAL PRESENTATION

The most important initial consideration in the patient who has sustained maxillofacial trauma is the evaluation of the patient's airway. Airway obstruction may result from



**Figure 4.** A, Normal orbital floor contour. B, Findings in classic orbital floor blowout fracture with subsequent enophthalmos.

**Table 1. NASO-ORBITAL ETHMOID FRACTURES**

Clinical Type	Fracture Pattern
Type 1	Isolated bony NOE injury
Type 2	Bony NOE and central maxilla
Type 2a	Central maxilla only
Type 2b	Central and one lateral maxilla
Type 2c	Central and bilateral maxillae
Type 3	Extended NOE injury
Type 3a	With craniofacial injuries
Type 3b	With Le Fort II and III fractures
Type 4	NOE with orbital displacement
Type 4a	With oculo-orbital displacement
Type 4b	With orbital dystopia
Type 5	NOE with bone loss

NOE = naso-orbital ethmoid fractures.  
Data from references 10 and 11.

intraoral hemorrhage, edema, loose teeth or dislodged dentures, and posteroinferior displacement of the maxilla. Performing a full general physical and a detailed neurologic examination, is important in this patient population. Concomitant cerebral injury is noted in over 50% of patients suffering from a fracture of the midface.<sup>13</sup> In the setting of facial trauma, low Glasgow coma scale scores (less than five) or radiologic evidence of intracranial hemorrhage is associated with a poor patient outlook in terms of survival.<sup>6</sup> Hence, in this scenario definitive fracture reduction and fixation should be delayed until the patient is more medically stable.

One should note the nature of the injury and consider the direction of the force trajectory causing the midfacial fracture. As a result of the presence of strong vertical buttresses, the midface is somewhat tolerant to vertically oriented force vectors, but readily fractures when exposed to laterally or obliquely directed force vectors. Determination of premorbid visual status as well as the patient's usual occlusion are also important considerations.

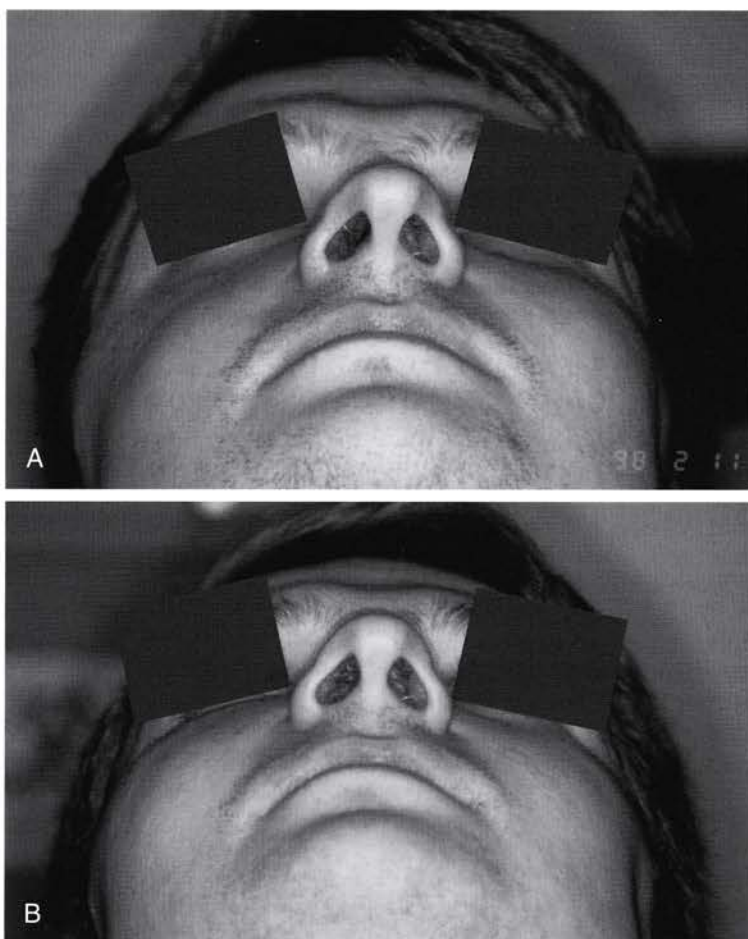
The specific signs noted in the individual patient, of course, depend on the degree of displacement and fracture comminution, as well as the presence or absence of associated fracture extension into the orbit or skull base. Commonly noted extensive facial edema may obscure underlying skeletal disruption. Palpation is, thus, the most informative segment of the physical examination in these patients. Often, there is just a palpable depression overlying the arch in the case of isolated zygomatic arch fractures. When zygomatic fractures accompany extensive fractures of the maxilla, however, the arch is often bowed outward

with a subsequent diminution of the anteroposterior projection of the malar eminence (Fig. 5). Occasionally, instead of simply being displaced inward, the body of the zygoma is rotated medially on a vertical axis, resulting in lateral rotation of the attached zygomatic arch. This leads to an abnormal prominence of the lateral midface. Classically, zygomatic complex fractures lead to palpable stepoffs and tenderness at the zygomaticofrontal and zygomaticomaxillary suture lines, as well as to disruption of the inferior orbital rim.

Often, it is possible to determine the general fracture pattern and the level of the fracture by grasping the anterior maxilla between the thumb and forefinger and attempting to rock the maxilla. The presence of pain, crepitus, or abnormal mobility provides the examiner with clues as to the presence of an underlying fracture. On occasion, gross midface instability can be demonstrated by asking the patient to bite down, resulting in upper movement of the maxilla. Motion noted at the level of the anterior nasal spine without simultaneous motion at the level of the nasal bones or body of the maxilla is characteristic of Le Fort I fractures.

In Le Fort II fractures, rocking the maxilla results in motion of the nasal pyramid, and often along with the medial orbital rims. Palpation may reveal periorbital findings of orbital rim stepoffs, infraorbital nerve paresthesia and anesthesia, and circumorbital edema and ecchymosis. The midface flattening and elongation characteristic of Le Fort II and III fractures is best appreciated by viewing the anterior facial form in a cephalad direction. Lack of motion at the level of the zygoma and zygomaticofrontal suture region clinically distinguishes Le Fort II from Le Fort III fractures. Although conductive anosmia may be noted in both types of fractures, sensorineural anosmia is more common in Le Fort III fractures because of the shearing forces that disrupt the olfactory filaments.

Le Fort III fractures are generally associated with the most severe midfacial edema, lengthening, and retrusion, otherwise known as a *dishface* deformity. Periorbital findings are often prominent features in this type of fracture. Craniofacial dysjunction results in movement of the entire middle third of the face while rocking the maxilla as previously described. Motion is elicited at nasofrontal, frontozygomatic, and zygomaticotemporal sutures. Classically, a Le Fort III fracture is associated with movement of the lateral orbital rim. If there is



**Figure 5.** A, Preoperative appearance of patient with severe right midfacial depression. B, Postoperative appearance of same patient following open reduction and internal fixation of midfacial fractures.

motion at the inferior orbital rim or a frontozygomatic suture stepoff, then consideration should be given to an associated fracture of the zygoma.

Intraoral examination may reveal the presence of loose teeth or mobile dentoalveolar segments. The mucosa overlying a palatal fracture may be disrupted or, more often, intact. Malocclusion is a common finding. Classically, one notes an anterior open bite deformity secondary to premature molar contact as a result of the posteroinferior displacement of the maxilla. This rotation of the maxilla away from its normal 45-degree angulation at the skull base, also leads to elongation and flattening of the midface. Severe trismus and pain are common complaints in patients with impingement or fracture of the coronoid process associated

with an isolated fracture of the zygomatic arch. The alveolar neurovascular bundles may be disrupted as they course to the upper dentition. This disruption causes early paresthesias of the upper dentition, and may lead to late devitalization of this same dentition. Subcutaneous emphysema, due to egress of air from disrupted paranasal sinuses, may be palpable in the midfacial tissues. If there is fracture extension to the level of the orbit, a range of ophthalmologic findings may be present. These can include relatively minor periorbital edema, ecchymosis, chemosis, or more serious, anterior or posterior chamber hemorrhages, retinal detachments, and visual loss. Orbital contents may herniate through defects in the orbital floor, leading to enophthalmos that may not be initially appreciable due to perior-

bital edema. Hertel ophthalmometry may assist the surgeon in making this diagnosis. Extraocular muscle entrapment or edema may be appreciated by noting the presence of limitation in globe movement. Most often, the inferior oblique muscle is entrapped. Forced duction testing should be used in confirming the diagnosis of entrapped orbital contents, and should be repeated intraoperatively whenever one has operated on the fractured orbital floor to confirm that the orbital contents have been fully released.

The lacrimal drainage system may also be disrupted. Generally, acute repair over a silastic stent needs only to be considered in the obviously transected canalicular system. Epiphora from disruption of the lacrimal drainage system occurs in 4% of Le Fort II and III fractures.<sup>1</sup> Interestingly, the most frequent indication for dacryocystorhinostomy in men is dacryostenosis resulting from midfacial trauma.<sup>32</sup> Late diagnosis of lacrimal injuries is commonly made many weeks after the initial injury. The presence of recurrent dacryocystitis, with medial canthal edema and tenderness, or recurrent purulence at the medial fornix, especially noted upon awakening in the morning, are clues to this diagnosis. Ophthalmologic consultation for the evaluation and treatment of the more serious eye injuries should be considered. In any case of midfacial fracture, documentation of visual status is mandatory before exploring any associated orbital fractures.

In the presence of continued nasal discharge, one needs to consider the possibility that a CSF leak may be present. Historical tests for glucose concentration (greater than two thirds of serum levels) and observation of a positive "halo" sign are not as accurate as immunohistochemical determination of the  $\beta_2$ -transferrin content.<sup>27</sup> The  $\beta_2$ -transferrin test is the most specific test available for CSF and is noted even in the presence of blood. One should make note that  $\beta_2$ -transferrin levels may also be elevated in the serum of cirrhotic patients. Generally, in fractures of the midface, the site of CSF leak is at the level of the cribriform plate of the ethmoid bone. Most CSF leaks that arise in the setting of acute midfacial trauma seal on their own with conservative treatment (bedrest with or without a lumbar drain). In the presence of a continued leak, however, consideration to its repair may be given at the time of definitive fracture repair.

Epistaxis and nasal obstruction are frequently noted in many patients with fractures of the maxilla. This may be the result of naso-septal disruption or secondary to the displaced segments of the maxilla itself. Epistaxis or minor bleeding from facial or intraoral lacerations is rarely life threatening. The major sources of such massive hemorrhage that need to be considered are the internal carotid artery at the level of the sphenoid and the internal maxillary artery at the level of the pterygopalatine fossa. Initial aggressive packing is required. Once stabilized, internal carotid artery disruption can be diagnosed and treated either by emergent surgical ligation or angiography-guided intra-arterial balloon occlusion. If this is unsuccessful, combined infratemporal fossa and middle cranial fossa approaches to the sphenoid may be required. If transection of the internal maxillary artery is suspected, a transantral approach with the use of hemoclips in the pterygopalatine fossa may be used. Embolization should also be strongly considered in this setting.

The symptoms of a naso-orbitoethmoid injury may vary because of the extent of displacement and comminution of the components. As mentioned, the nasal bridge is often displaced posteriorly with splaying of the nasal complex. Epistaxis, periorbital edema and ecchymosis, and CSF leak may be present. Mobility of the nasal complex in all directions helps to confirm the diagnosis. Lateral traction applied at the level of the lateral canthus to evaluate medial canthal mobility should be undertaken. Disruption of the medial canthal ligament results in traumatic telecanthus. The average intercanthal distance of 32 to 38 mm is, of course, dependent upon the gender and the race of the individual. Measurement in the acute setting is often difficult because of the presence of surrounding edema. Thus, interpupillary approximation may be of benefit.

## RADIOLOGIC ASSESSMENT

Before imaging the facial bones, one needs first to consider the possibility of cervical spine (C-spine) injury. To this end, a full C-spine series (including the seven cervical and first thoracic vertebrae) needs to be obtained. If no abnormality is detected on these preliminary films, patient-directed flexion and extension views may be considered. In the obtund or

otherwise unreliable patient, CT scan of the spine and neurologic consultation or MR image may be required fully to clear the C-spine. Complete imaging of the facial bones, especially in the coronal plane, is not always possible if the C-spine has not been cleared.

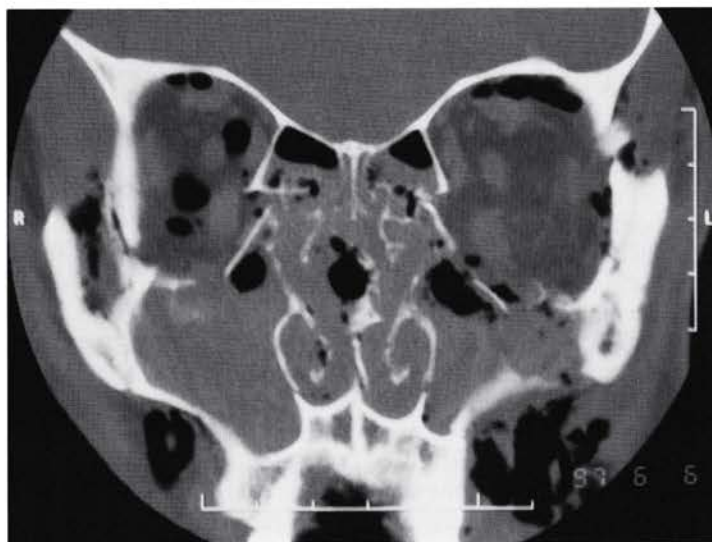
The diagnosis of fractures of the midface is suspected from the history and physical examination. The diagnosis is confirmed with ancillary radiologic investigations (Fig. 6). Simple dentoalveolar fractures are best visualized with a panorex or dental periapical examination. In the past, and presently where CT is unavailable, plain radiographs (Caldwell, Waters, lateral, and submentovertex) were utilized for demonstration of these fractures. The vast majority of these fractures can be visualized on plain radiographs. CT scanning, however, in the coronal and axial planes, offers a clearer delineation of the degree of displacement and comminution that may be present. It also allows for visualization of critical areas that are generally not well seen on plain radiographs, such as the orbital apex. Axial cuts show fractures of the posterior wall of the antrum, pterygoid plates, hard palate and dentoalveolar segments, zygomatic arch, body of zygoma, and lateral wall of the orbit. Coronal images are most useful for demonstrating fractures of the anterior maxilla, inferior orbital rim, palate, and orbital floor. In spite of the outlined benefits, no study to date has con-

firmed the cost effectiveness of routine CT scanning in the evaluation of all midfacial fractures. Three-dimensional CT scans provide excellent spatial orientation. Their value, however, probably lies more with secondary reconstructive efforts. In the acute setting, many of the radiographs, including CT scans, can be obtained as a part of the general patient survey. In fact, many trauma centers have standing protocols when there is any suggestion of head and neck trauma.

## PRINCIPLES OF TREATMENT

Initial attention should be directed to securing a stable airway and controlling any epistaxis or oral bleeding. Concurrent multisystem and central nervous system injury is often found in these polytrauma victims. Consequently, immediately or imminently life-threatening injuries need to be addressed before full assessment of any midfacial fractures may proceed.

In the patient suffering from obvious trauma to the midface and presenting with a tenuous airway, oral intubation with in-line traction for C-spine protection is the preferred method of securing the airway. Intracranial passage of the endotracheal tube from an attempted nasotracheal intubation is highly unlikely even with severe midface trauma. Not only does



**Figure 6.** Coronal CT scan demonstrating classic craniofacial disjunction noted with LeFort III fractures.

this possibility exist, however, but there is an even greater chance that nasotracheal intubation may result in further disruption of any fractures that may be present in the floor of the anterior cranial fossa. If there is concomitant laryngeal injury or a clearly unstable C-spine, the airway should be secured with tracheotomy or cricothyrotomy.

Often, surgical intervention for other organ system injuries is initially required. A tracheotomy with or without the application of arch bars may often be performed at the same initial surgical intervention without significantly prolonging the procedure in a potentially unstable patient.

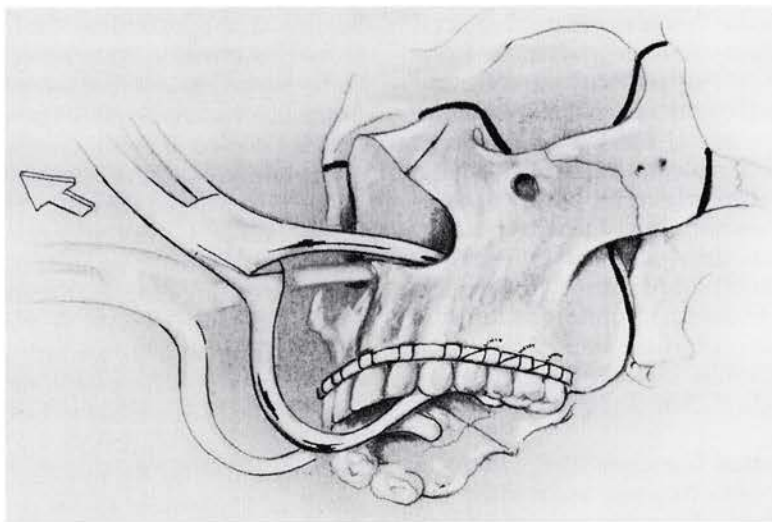
All patients with fractures of the maxilla should receive prophylactic antibiotics because most midfacial fractures are considered to be open. Even if there is no mucosal disruption present, the surgical approaches to these fractures necessitate violating the mucosal barrier. The risk of infectious complications is likely decreased by the routine use of such antibiotics.<sup>21</sup> We often also give our patients 24 to 48 hours of intravenous steroids (e.g., dexamethasone) to help control some of the perioperative edema that is commonly noted with fractures of the maxilla and their repair.

Before embarking on surgical stabilization of a midface fracture, one needs to first determine whether or not surgical intervention is even appropriate. A clinically and radiologically nondisplaced fracture usually can be managed conservatively with a soft pureed diet for 4 to 6 weeks to reduce the masticatory load. If there is clinical or radiologic evidence of complete healing at the end of this trial period, advancement to a normal diet may be attempted. In edentulous patients who display a small amount of fracture displacement, but where the fracture appears to be able to withstand modified (soft diet) masticatory forces, strong bony union is usually the result of conservative treatment alone.<sup>31</sup> Later modification of the patient's dentures to reflect the new spatial relationship between the upper and lower jaws causes little to no long-term problems in this patient population. Finally, if the patient is suffering from such severe systemic or cerebral injury that the chance of survival is low, surgical intervention for repair of midfacial fractures should not be attempted.

There exists no universally accepted time frame for the treatment of fractures of the midface. Early midfacial skeletal realignment and

fixation, in theory, reduce the likelihood of soft tissue contraction overlying the fractures. Some surgeons feel that such irreversible soft tissue contraction reliably occurs if fracture repair is delayed beyond 2 weeks from the time of the injury.<sup>11</sup> If there is evidence of intracranial hypertension ( $>15$  mm Hg), one should postpone surgical intervention because of the significant increase in intracranial complications (including exacerbation of edema and intradural hemorrhage) that may result.<sup>2</sup> If the patient is unable to tolerate a long surgical procedure and, where definitive fracture treatment appears like it has to be delayed beyond 2 weeks, consideration should be given to at least disimpacting the maxilla (if required) and securing the patient in his or her premorbid occlusion with the use of arch bars. By thus bringing the maxilla into a more normal relationship with the lower jaw, less overlying soft tissue contraction is expected to occur. Generally, in the stable patient, it is recommended that fracture reduction and stabilization be carried out within 7 to 10 days of the injury.<sup>20</sup>

One always needs to achieve a normal occlusal relationship prior to the placement of any rigid internal fixation devices. Disimpaction is first performed by placement of the straight blade of a Rowe and Killey disimpaction forceps intranasally, and the angulated blade intraorally.<sup>26</sup> Disimpaction is carried out by reversing the action of the pterygoids (Fig. 7). Thus, the maxilla should be brought out anteriorly and superiorly, with re-establishment of its normal angulation with the skull base. Generally, arch bars and maxillomandibular fixation need to be maintained for 4 to 6 weeks postoperatively if there has been severe comminution of the buttresses, requiring bone grafting or where solid skeletal reconstruction of the buttresses was not able to be achieved with the use of rigid internal fixation. If the vertical buttresses were rigidly fixated, with the achievement of solid bony support, however, maxillomandibular fixation and arch bars may be removed safely at the completion of the procedure. In patients with an inadequate native dentition (pediatric patients with a mixed dentition, mostly edentulous individuals, and so forth) that precludes the placement of arch bars, Ivy loops, occlusal splints, or dentures may be required. If the patient has an associated fracture of the mandible, it should



**Figure 7.** Midfacial disimpaction with Rowe forceps. Note anterosuperior movement.

be reduced and rigidly fixated before repair of midfacial fractures.

Closed reduction of displaced fractures of the midface is uncommonly appropriate. It is worthwhile in isolated simple dentoalveolar fractures. In more anatomically complex midface fractures, however, failure to fixate rigidly the maxilla or zygomatic complex often results in malunion and esthetically displeasing elongation of the middle third of the face or flattening of the malar eminence with long-term enophthalmos.

A number of methods of craniofacial wire suspension for the treatment of fractures of the midface have been described.<sup>7</sup> Secondary late deformity is common after use of this fixation method. Untreated Le Fort fractures result in midface elongation; however, treatment with wire suspension commonly leads to midface compression and retrusion. In excess of 60% of Le Fort fractures treated with craniofacial suspension techniques can be expected to heal with the maxilla in a cosmetically and functionally unfavorable posterosuperior position.<sup>8</sup> Steinman pin fixation and Kirschner wires are not used in our practice. Not only do they provide for nonrigid fracture stabilization, they also allow for rotation around a single point of fixation, jeopardizing proper fragment reduction. In an effort to overcome this lack of anterior projection and loss of vertical height, external fixation devices were used. Proper application of these devices is difficult. Continual required adjustments over the nec-

essary 6- to 8-week period of use and the sheer bulkiness of the device made it quite uncomfortable for the patient to tolerate. Moreover, adjustments of the frame are difficult to judge and more often than not are based on rough estimations of what "looks right" rather than on firm anatomic landmarks. External frames do not provide absolutely rigid fracture fixation. The role of wires in the fixation of fractures of the midface has largely been relegated to temporary intraoperative use to facilitate application of rigid fixation devices and to bring numerous comminuted fracture fragments together prior to fixating the now reconstructed larger segment with plates. Some surgeons still describe good success with the use of suspension wires in the patient with intact solid vertical buttress support. This clinical scenario is not encountered often in practice. Wires may also be used for the treatment of simple fractures of the hard palate where the upper dental arch is going to be maintained in arch bar support for 4 to 6 weeks.

Miniplate fixation has revolutionized the treatment of fractures of the midface. Rohrich et al<sup>25</sup> found a significantly lower complication rate and more accurate globe and cheek position when miniplates were utilized as compared with wires. Proper application allows for normal or near normal restitution of the three-dimensional projection of the midface. If there is solid bone-to-bone contact present, then primary bone healing results. Numerous authors have reported excellent success with

the use of noncompression miniplate systems for the treatment of midfacial fractures.<sup>10, 28</sup>

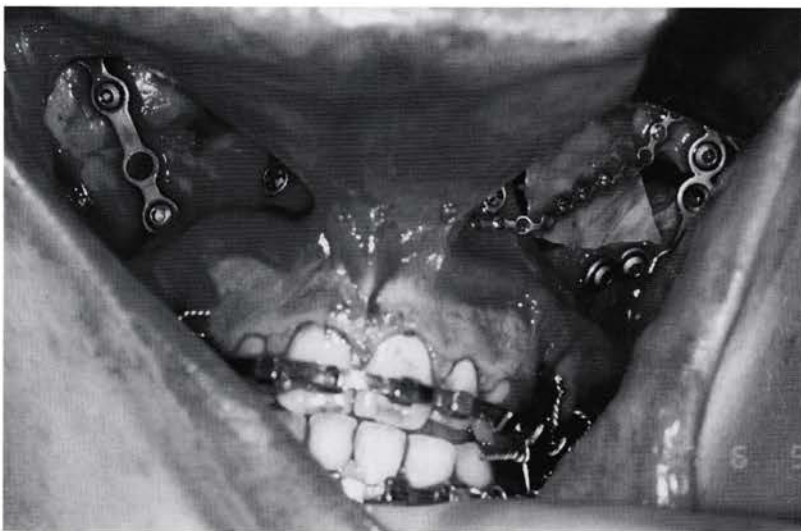In order to visualize fully the fractured maxillary segments to allow for the application of rigid fixation, excellent exposure is mandatory. On occasion, one is able to utilize existing lacerations to view and stabilize the fracture segments. Practically, unless one is dealing with a simple fracture of the hard palate with overlying mucosal disruption, to visualize the necessary fractured segments fully, certain standard surgical approaches need to be used.

The workhorse of approaches to the midface is the maxillary vestibular approach. The incision generally extends from the midline to the first or second molar. Bilateral incisions may also be made to facilitate a degloving approach that may be required for exposure. Excellent exposure to the medial and lateral vertical buttresses, medial maxilla, and anterior face of the maxilla is provided by this approach. A gingivobuccal approach is required in all fractures of the maxilla to allow full assessment and fixation of the vertical buttresses (Fig. 8).

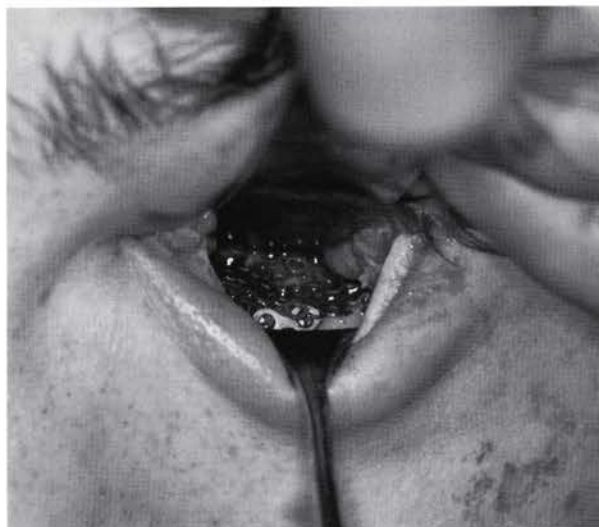When one is dealing with a Le Fort II, Le Fort III, or zygomatic complex fracture, exposure of the orbital rim and floor is often required. This can variably be performed via a subciliary or transconjunctival approach. We prefer to use the transconjunctival approach because it has less postoperative edema and lower lid ectropion than the subciliary approach, and it avoids a facial incision. If further lateral expo-

sure is required, one can easily perform a lateral canthotomy with inferior cantholysis (Fig. 9). Excellent exposure of the lateral orbital rim can now be obtained. When access to the zygomaticofrontal suture area is needed for the placement of fixation devices, a brow incision was traditionally recommended. We prefer, instead, to use an upper blepharoplasty-type incision that is well camouflaged postoperatively within the upper eyelid sulcus. Care must be taken not to extend this incision so far laterally that one might inadvertently damage the frontal nerve branch of the facial nerve.

The classic approach to fractures of the zygomatic arch is the Gillies technique.<sup>9</sup> Here, a 2-cm incision is made in the temporal scalp or temporal hair tuft, approximately 2 cm within the hairline. Dissection is carried through and under the superficial layer of the deep temporal fascia. The frontal branch of the seventh cranial nerve is not at risk of transection if one stays below this fascial layer. An elevator (we prefer to use the Boies elevator for this purpose) is then tunneled below this fascia, and under the zygomatic arch. The displaced fractured arch is then disimpacted and rotated laterally into its proper anatomic position. Visualization of the fractured arch is not possible with this approach unless it is combined with another surgical approach. Proponents feel that such a maneuver allows the fractured segments to slide or snap into place, and be maintained in such a position by the splinting ef-



**Figure 8.** Access to plating of maxillary buttresses obtained by way of bilateral upper gingival incision.



**Figure 9.** Access for application of titanium mesh orbital floor reconstruction gained through a transconjunctival approach. Addition of a lateral canthotomy has allowed for increased exposure.

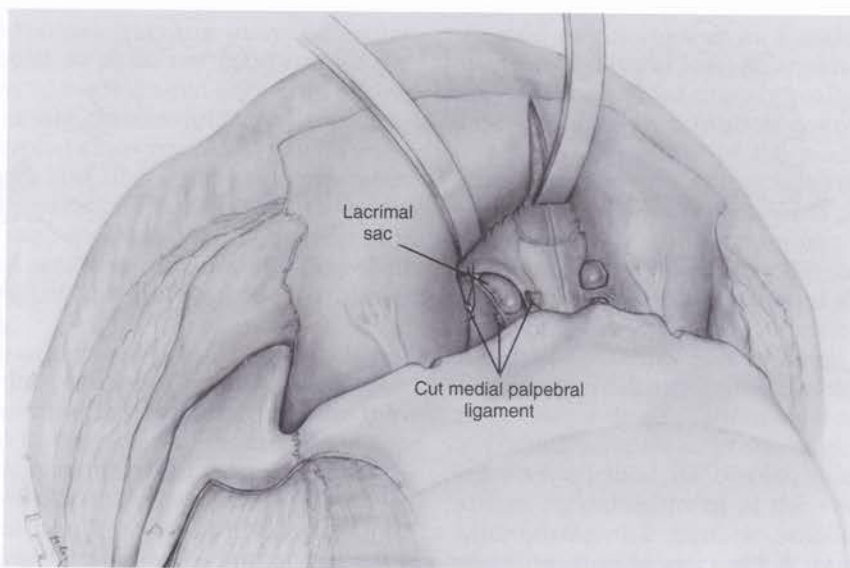
fects of the underlying temporalis muscle. An external splint may also be used in mildly unstable fractures after reduction. Postoperatively, patients in whom no fixation has been utilized should be placed on a soft or fluid diet for 3 to 6 weeks to reduce the discomfort felt when a full masticatory load is exerted on the healing fractures. Although this is a simple technique to use, that may leave the patient with a reasonable esthetic and functional outcome, the lack of fixation and lack of direct fracture visualization may result in derangement of the normal anatomic configuration of the zygomatic complex. In fact, Melmed<sup>23</sup> demonstrated that, even in the low velocity, minimally displaced arch fractures that are normally considered to be the best candidates for this treatment option, there is a 30% rate of outcomes that were rated as being unacceptable (functionally and esthetically).

The coronal flap incision provides the best exposure of the frontal bar region, zygomatic arches, and root of the nose (Figs. 10 and 11). It is thus the ideal approach for rigid fixation of most Le Fort III fractures and severe fractures of the zygomatic arch (Fig. 12).

### SITE-SPECIFIC TREATMENT

The goals of treatment of Le Fort I fractures are the restoration of a normal occlusal rela-

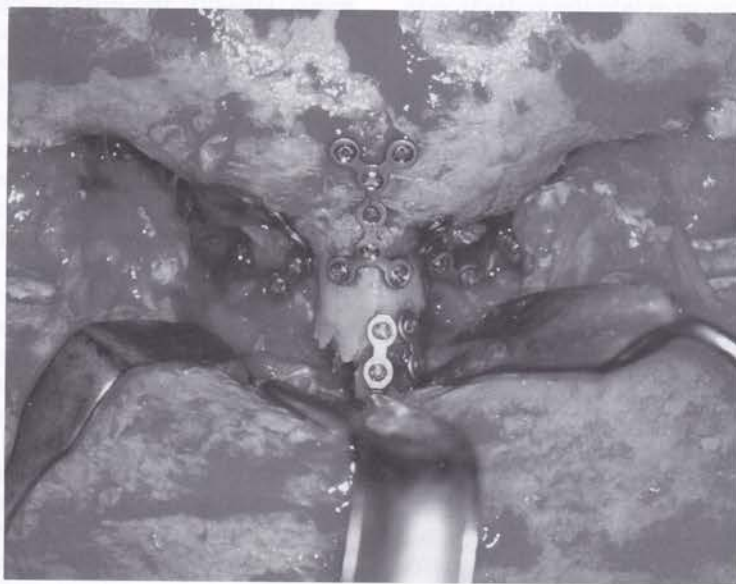
tionship and appropriate vertical height to the midface. The palatal segment needs to be stabilized and any septal dislocations need to be repaired. As for all fractures of the maxilla, initial disimpaction and placement of arch bars should be considered mandatory to provide reliably for correct spatial orientation of the maxilla. Select stable low fractures of the maxilla may occasionally be managed with closed reduction and maxillomandibular fixation for a period of 6 to 8 weeks. If there has not been significant comminution or bone loss present and rigid fixation was achieved, removal of arch bars at the conclusion of the procedure is often possible. We generally utilize miniplate osteosynthesis in the treatment of these fractures. Any palatal fractures are rigidly fixated before the application of maxillomandibular fixation to allow for re-establishment of the patient's normal occlusion. The maxillary vestibular approach is then utilized to access the anterior maxilla. The key in reconstructing these fractures is the proper repositioning of the vertical buttresses. At least two screws need to be placed on either side of the fracture line. One needs to be careful to avoid the tooth roots when fractures extend inferiorly in the zygomaticomaxillary buttress. To this end, the use of L-shaped plates is invaluable for allowing placement of enough screws across the inferior aspect of the fracture, while still avoiding



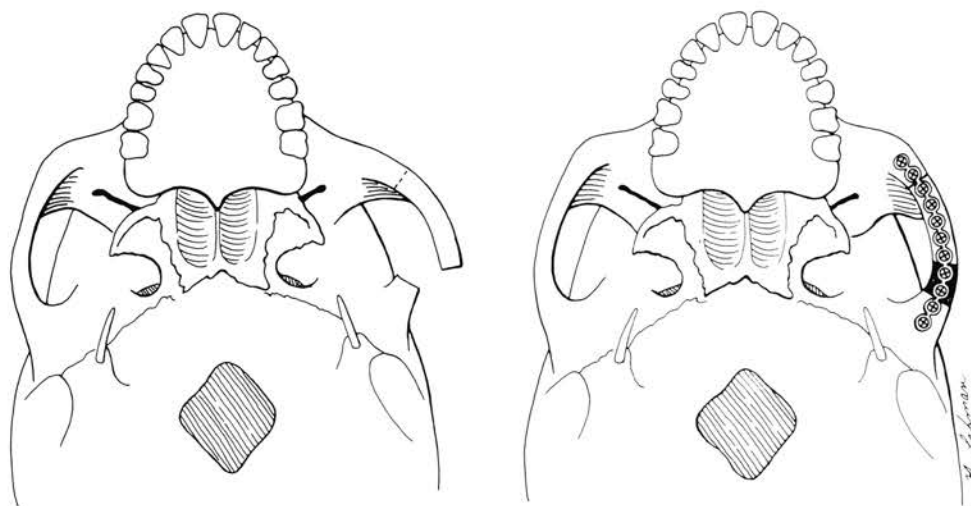
**Figure 10.** Coronal approach to Le Fort III fractures.

the tooth roots. Generally, one or two plates are required to rigidly fixate each buttress. To absorb the masticatory load better, we prefer to use sturdier miniplates (usually 1.7 mm) in buttress reconstruction. When there is bone loss within one of the vertical buttresses, it should generally be bridged by the use of bone grafts. We prefer to use calvarium. The use of

iliac crest or rib grafts, however, is also acceptable. The key to preventing resorption of these bone grafts is rigid in situ fixation. Generally, fixation is easiest to accomplish with the use of lag screws. Lessons learned from orthognathic surgery have shown bridging gaps with plate fixation alone may lead to relapse and alteration of the occlusion. Bony gaps of less than



**Figure 11.** Intraoperative demonstration of access afforded for open reduction and internal fixation (ORIF) at nasal root.



**Figure 12.** A, Basal view of displaced isolated arch fracture. B, ORIF is most reliable method of obtaining consistently rewarding results in the treatment of this injury.

0.75 cm may be bridged safely with miniplates (and postoperative maxillomandibular fixation) without the need for interpositional bone grafting. When all four anterior vertical buttresses are comminuted, correct repositioning can only be accomplished by aligning the contours of the bone fragments and relying on esthetic norms for midface proportion (middle third of face = upper third = lower third of face). When bone grafting is required for buttress reconstruction, or when the reduction is not absolutely rigid, maxillomandibular fixation should be maintained postoperatively.

The initial sequence of repair for Le Fort II fractures is as described for Le Fort I fractures. In Le Fort II fractures, one must, in addition, explore the orbital rim and floor. Fractures of the rim are best repaired with wires or low profile (so as not to be palpable) miniplates (1.2 mm). If there is bone loss at the level of the inferior orbital rim, it needs to be reconstructed to prevent the significant postoperative cosmetic deformity that results if it is left unrepaired. Often, small pieces of bone from comminution around this site are available for reconstruction. If necessary, bone grafts should be harvested and rigidly fixated to any remaining rim segments. Comminution of the orbital floor may be variably treated depending on the size of the defect that is present. For defects less than 1 cm, simple application of gelfilm suffices. For larger defects, titanium mesh, titanium foil, resorbable mesh, other al-

loplasts, or bone grafts may be utilized. Whatever the material used for floor reconstruction, it needs to be fixated to the inferior rim with either a semipermanent suture; screw; or miniplate. This is necessary to prevent posterior migration or displacement of the reconstruction material toward the orbital apex, thus, potentially placing the optic nerve at risk.

The approach to Le Fort III fractures is again initially similar to the more inferior fracture levels. Usually, the medial and lateral vertical buttresses need to be re-established first. Miniplates generally also need to be applied to the nasofrontal, zygomaticofrontal, and zygomaticotemporal areas. These are best placed in position via a coronal approach. If there are significant forehead lacerations already present, these may be utilized. A midforehead incision hidden in a prominent rhytid may also be used. The so-called *open sky* (bilateral brow incisions connected via a transglabellar incision) should generally be avoided due to the poor esthetic outcomes associated with its use. The orbital rims are reconstructed as previously described. The nasal bridge is often severely collapsed. Reduction with Asche forceps and plate fixation of the nasal fracture in conjunction with intranasal silastic stents often corrects this. At times, anterior repositioning of the nasoseptal complex, resuspension of the dislocated upper lateral cartilages, with or without autogenous bone or rib graft dorsal reconstruction may be necessary. Severely

comminuted nasal fractures may be better closed-reduced so as to not compromise the blood supply to the fractured segments, allowing for a more successful later septorhinoplasty. Frontal sinus fractures may be associated with Le Fort III fractures. Incumbent in the decision-making to obliterate the sinus is patency of the nasofrontal ducts, presence of intact frontal sinus septum, and the degree of comminution of the frontal bones or sinus itself.

When repairing medial maxillary fractures, wires may be preferable because even low-profile plates may be visible through the thin skin present in this area of the face. If the use of miniplates is required for fracture stabilization, they often have to be removed at a secondary procedure 3 to 6 months after fixation. As outlined, palatal fractures are treated with miniplates prior to the application of maxillo-mandibular fixation. Palatal splints may, however, be required in very severely comminuted fractures of the palate.

Displaced fractures of the zygoma may be isolated arch fractures or true zygomatic tripod complex fractures. Isolated arch fractures are usually the result of direct force of low velocity, and may be associated with coronoid process fractures. A localized depression of the cheek is diagnostic with or without trismus. Noncomminuted bony disruptions may be managed with closed reduction techniques, such as an extraoral Gillies or intraoral Kean approach. If adequate restoration of form is achieved and maintained by the splinting effect of the temporalis fascia and masseter muscles, then rigid fixation is not necessary. Reproduction of its normal form is essential to the anterior facial projection and width. In the case of a comminuted arch fracture or where the arch does not maintain its position, then an external splint, such as an eye shield, metal finger splint, or rigid plastic material of some form may be used as a guard that prevents the patient from directing any force to that site. These reduction techniques, however, allow mobility and rotation. In this instance, rigid fixation via a direct approach to the arch is favored. The standard approach is via a coronal exposure. Alternatively, the authors have had good experience using endoscopic trans-temporal approaches.

Displaced zygomatic complex (tripod) fractures require open reduction and internal fixation. Fractured segments should be reduced

as soon as possible before a malunion occurs, usually 10 days or less. A large hook or elevator may be placed transbuccally behind the body of the zygoma to allow controlled manipulation. Disinsertion of the masseter muscle may be required for complete reduction. The extent of exposure is somewhat dependent on the degree of arch displacement. If the zygomatic arch component of the complex arch fracture is minimally displaced and adequate anterior facial projection is maintained, then two-point fixation is sufficient. Three-point fixation provides the most stable reconstruction. Use of 1- or 1.2-mm microplates at the zygomaticofrontal suture through an extended transconjunctival or blepharoplasty incision allows reestablishment of the vertical height. Microplates, 1.2 mm or smaller, are then placed at the inferior orbital rim through the same transconjunctival incision. Finally, a sublabial incision allows 1.7- or 2-mm miniplates to be placed at the zygomaticomaxillary buttress. Two-point fixation (zygomaticofrontal and zygomaticomaxillary) provides adequate stability in a majority of cases.

When assessing the complex zygomatic arch fracture reduction the zygomaticofrontal suture area provides the poorest indicator of zygomatic arch rotation, but best for vertical height. Temporary wire stabilization may allow the surgeon to verify correct alignment of the other fracture sites before rigid fixation. The most dependable source for predicting correct alignment of a complex tripod fracture is the exact repositioning of the greater wing of the sphenoid within the lateral orbital wall. Once an accurate assessment is made, rigid osteosynthesis proceeds in a systematic manner. Usually, the anterior projection is established by plating the zygomatic arch, then fixation at other sites proceeds.

Midface fractures in children account for 10% of all fractures to the pediatric facial skeleton.<sup>22</sup> The infant's face is small relative to total head size, with the midface being flat and decreased in its vertical dimension. The inherent flexibility of the child's craniofacial structure lends it prone to greenstick-type osseous injuries. This, in combination with the lack of sinus pneumatization, contributes to the relative resistance of the pediatric midface to traumatic disruption. The developing dentition makes identification of fracture lines difficult in this population on plain radiographs. CT is, thus, a more beneficial study. Bony union occurs at

a more rapid pace; therefore, reduction and fixation should be carried out with this in mind. The basic principles of reconstruction are the same as in the adult population, except the care necessary when placing plates and screws, so as to avoid injury to developing tooth buds. There may also be a need to remove metal plates and screws in light of the possibility of arrested midfacial growth and plate migration associated with rigid osteosynthesis in this patient population. Today, the use of resorbable products may preclude this issue. If plates are used, they should generally be removed in 3 to 6 months. If maxillomandibular fixation is required, it is generally not continued beyond 2 to 4 weeks.

## COMPLICATIONS

Complications following midface fractures occur as a result of improper technique, delayed therapy, or infection. There is also a direct relationship between the severity of the injury and the incidence of complications. The more complex the repair, the more difficult it is to "fit the pieces of the puzzle together." Severe comminution of midfacial buttresses associated with bone loss makes rigid fixation more difficult.

Malunion is uncommonly seen with use of rigid fixation techniques. Malocclusion with dental prematurities may be present. When it has occurred, orthognathic reconstruction is necessary, usually with the removal of the previous hardware. Nonunion is rare but usually caused by early mobilization. The excellent blood supply of the midfacial skeleton also aids in this endeavor, as well as preventing infection and possible osteomyelitis. Most late postoperative infections are attributable to screw or plate loosening, requiring hardware removal. Despite all of this, minor dental discrepancies are often noted, and can be resolved with an appropriate referral.

The most serious complications of fractures of the midface are of ophthalmologic origin. Total loss of vision following reduction of zygomatic fractures is unusual, with only 20 reported cases.<sup>17</sup> Blindness may occur as a result of the injury secondary to bone impaction along the course of the optic nerve, or aggravation of an existing problem, such as glaucoma. If there is radiologic evidence of near-impingement of the orbital apex or optic nerve,

reduction of the associated fragments may cause more serious injury. Recognition is necessary either to institute steroid therapy or to decompress the optic nerve.

Persistent diplopia is relatively common, occurring in 7% of patients (most often in the upper visual fields).<sup>17</sup> Long-term enophthalmos is usually avoided with accurate fracture repair. Persistence of such deformity may be caused by fat atrophy or herniated orbital contents. Eleven percent of patients continue to experience marked enophthalmos.<sup>12</sup> Perioperative edema makes accurate reduction difficult in severely comminuted fractures of the orbits and associated facial skeleton.

Persistent lower lid edema is often a consequence of a subciliary approach to the inferior orbital rim and floor. Likewise, ectropion is seen less commonly when using a transconjunctival approach. Spontaneous resolution of both may be hastened by daily massage of the area.

Eesthetic deformity from improper repositioning of the midface may be seen. Incomplete maxillary disimpaction creates midface retrusion. An anterior open bite may also be noted. Telecanthus can be avoided with proper resuspension of the medial canthal ligaments. Care should also be taken in properly suspending the lateral canthi. Resuspension of the soft tissues of the midface is required to prevent facial laxity. Reapproximation of the periosteum at the inferior orbital rim may prevent cheek mound ptosis, whereas closing the deep temporal fascia may help to decrease the eventual temporal wasting seen with many coronal approaches. Of course, careful initial dissection without devitalizing the temporal fat pad may help as well.

Paresthesia and anesthesia of the supra-trochlear, supraorbital, and infraorbital nerves are quite common depending on the injury mechanism. Disturbing them during fracture repair should be avoided. Most affected patients see progressive improvement of their symptoms over as long a period as 18 months; however, some chronic residual sensory deficit is not unusual.

Nasal obstruction and external nasal deformity are relatively common sequelae of severe midface fractures. Dorsal elevation and placement of intranasal stents aid in the re-establishment of a patent nasal airway. Establishment of dorsal projection may require immediate bone grafting. Failure to

re-establish dorsal height may result in soft tissue contraction.

## References

1. Belle VH, Anderson R, Siim C: Incidence of lacrimal obstruction following trauma to the facial skeleton. *Ear Nose Throat J* 67:66, 1988
2. Brandt KE, Buruss GL, Hickerson WL, et al: The management of midface fractures with intracranial injury. *J Trauma* 31:15, 1991
3. Cooter RD, David DJ: Computer based coding of fractures in the craniofacial region. *Br J Plast Surg* 42:17, 1989
4. Dal Santo F, Ellis E, Throckmorton CS: The effects of zygomatic complex fractures on masseteric muscle force. *J Oral Maxillofac Surg* 50:791, 1992
5. David DJ, Cooter RD: Craniofacial infection in 10 years of transcranial surgery. *Plast Reconstr Surg* 80:213, 1987
6. Derdyn C, Persing JA, Broaddus WC: Craniofacial trauma: An assessment of risk related to timing of surgery. *Plast Reconstr Surg* 78:9, 1986
7. Donald PJ: Maxillary fractures. In Donald PJ, Gluckman JL, Rice DH (eds): *The Sinuses*. New York, Raven Press, 1994, p 303
8. Ferrano JW, Berggren RB: Treatment of complex facial fractures. *J Trauma* 13:783, 1973
9. Gillies HD, Kilner TP, Stone D: Fractures of the malar zygomatic compound with description of a new x-ray position. *Br J Surg* 14:651, 1927
10. Gruss JS, Phillips JH: Complex facial trauma: The evolving role of rigid fixation and immediate bone graft reconstruction. *Clin Plast Surg* 16:93, 1989
11. Gruss JS, Van Wyck L, Phillips JH, Antonyshyn O: The importance of the zygomatic arch in complex midfacial fracture repair and correction of posttraumatic orbitozygomatic deformities. *Plast Reconstr Surg* 85:878, 1990
12. Harley RD: Surgical management of persistent diplopia in blowout fractures of the orbit. *Ann Ophthalmol* 7:1621, 1975
13. Haug R: An epidemiologic survey of facial fractures and concomitant injuries. *J Oral Maxillofac Surg* 48:926, 1990
14. Haug R, Savage JD, Likavec MJ, Conforti PJ: A review of 100 closed head injuries associated with facial fractures. *J Oral Maxillofac Surg* 50:218, 1992
15. Jackson IT: Classification and treatment of orbitozygomatic and orbitoethmoid fractures: The place of bone grafting and plate fixation. *Clin Plast Surg* 16:77, 1989
16. Jelks GW, LaTrenta G: Orbital fractures. *Surgery of Facial Bone Fractures*. In Sherman JE (ed): New York, Churchill Livingstone, 1987, p67
17. Karlan MS: Complications of malar fractures. In Mathog RN (ed): *Maxillofacial Trauma*. Baltimore, Williams and Wilkins, 1984, p 350
18. Knight JS, North JF: The classification of malar fractures: An analysis of displacement as a guide to treatment. *Br J Plast Surg* 13:325, 1961
19. Le Fort R: Etude experimental sur les fractures de la machoire superieure. *Rev Chir* 23:208, 1908
20. Manson PN, Crawley WA, Yaremchuk MJ, et al: Midface fractures: Advantages of immediate extended open reduction and bone grafting. *Plast Reconstr Surg* 76:1, 1985
21. Manson PN, Hoopes JE, Su CT: Structural pillars of the facial skeleton: An approach to the management of Le Fort fractures. *Plast Reconstr Surg* 66:54, 1980
22. McGraw B: Pediatric maxillofacial trauma: Age related variations in injury. *Arch Otolaryngol Head Neck Surg* 116:41, 1990
23. Melmed EP: Fractures of the zygomatic malar complex. *S Afr Med J* 46:569, 1972
24. Nahum AM: The biomechanics of maxillofacial trauma. *Clin Plast Surg* 2:59, 1975
25. Rohrich RJ, Hollier LM, Watermull D: Optimizing the management of orbitozygomatic fractures. *Clin Plast Surg* 19:149, 1992
26. Rowe NL, Killey HC: *Fractures of the Facial Skeleton*. Edinburgh, Livingstone, 1955
27. Ryall RG, Peacock MK, Simpson DA: Usefulness of beta2 transferrin assay in the detection of cerebrospinal fluid leaks following head injury. *J Neurosurg* 77:737, 1992
28. Schilli W, Ewers R, Niederdelmann H: Bone fixation with screws and plates in the maxillofacial region. *Int J Oral Surg* 10:329, 1981
29. Shumrick DA: Malar zygomatic fractures in maxillofacial trauma. In Mathog RN (ed): *Maxillofacial Trauma*. Baltimore, Williams and Wilkins, 1984, p 340
30. Sullivan WG: Maxillary fractures. In Sherman JE (ed): *Surgery of Facial Bone Fractures*. New York, Churchill Livingstone, New York, 1987:151
31. Thaller SR, Kawamoto HK: A histologic evaluation of fracture repair in the midface. *Plast Reconstr Surg* 85:196, 1990
32. Zolli CL, Shannon GM: Dacryocystorhinostomy: A review of 119 cases. *Ophthalmic Surg Lasers* 13:905, 1982

Address reprint requests to

Yadranko Ducic, MD, FRCS(C)  
JPS Health Network  
1500 South Main Street  
Fort Worth, TX 76104