

Contents lists available at [ScienceDirect](#)

Clinical Oncology

journal homepage: www.clinicaloncologyonline.net

Overview

Rare Thyroid Malignancies: an Overview for the Oncologist

D.B. Spielman^{*}, A. Badhey[†], S. Kadakia[‡], J.C. Inman[‡], Y. Ducic[§]^{*} Albert Einstein College of Medicine, Bronx, NY, USA[†] Department of Head and Neck Surgery, New York Eye and Ear Infirmary of Mount Sinai, New York, NY, USA[‡] Department of Otolaryngology/Head and Neck Surgery, Loma Linda University Health, Loma Linda, CA, USA[§] Department of Head and Neck Surgery, Otolaryngology and Facial Plastic Surgery Associates, Dallas-Fort Worth, TX, USA

Received 19 November 2016; received in revised form 7 January 2017; accepted 19 January 2017

Abstract

Anaplastic thyroid cancer, medullary thyroid cancer, primary thyroid lymphoma and primary thyroid sarcoma are rare thyroid cancers that comprise 5–10% of all thyroid malignancies. Unlike well-differentiated thyroid cancers, these malignancies have few treatment options and carry a worse prognosis. The literature surrounding these pathologies is limited, but remains an area of active research. Despite the rarity of these conditions, they remain an important part of the differential diagnosis for any thyroid nodule. Awareness of their presentation, work-up and management is critical for oncologists and head and neck surgeons. The purpose of this article is to provide a broad overview of these malignancies with an emphasis on emerging clinical research and therapies.

© 2017 The Royal College of Radiologists. Published by Elsevier Ltd. All rights reserved.

Key words: Anaplastic thyroid carcinoma; medullary thyroid cancer; primary thyroid lymphoma; primary thyroid sarcoma; thyroid cancer

Statement of Search Strategies Used and Sources of Information

PubMed, Cochrane Library and ClinicalTrials.gov were queried for ‘anaplastic thyroid cancer’, ‘medullary thyroid cancer’, ‘thyroid lymphoma’, ‘thyroid sarcoma’, ‘undifferentiated thyroid cancer’, ‘poorly differentiated thyroid cancer’ and ‘head and neck sarcoma’. All relevant articles were reviewed and incorporated as appropriate.

Introduction

The National Cancer Institute estimates that about 64 300 new thyroid cancer diagnoses were made in 2016 in the USA. Most patients with thyroid malignancies have well-differentiated lesions [1–3]. These malignancies have been extensively studied and have consensus guidelines for diagnosis and management. The minority of patients outside

of this category, comprising about 5–10% of all patients with thyroid cancer [4], carry a diagnosis of a rare thyroid cancer with an uncommon aetiopathogenesis. As a result of the low incidence of these malignancies, there is a paucity of literature and often a lack of evidence-based physician congruency regarding management. This review coalesces the literature to provide interdisciplinary teams with an overview of these pathologies. We highlight the newest evidence regarding disease presentation and management for the following four malignancies: anaplastic thyroid cancer (ATC), medullary thyroid cancer (MTC), primary thyroid lymphoma (PTL) and primary thyroid sarcoma (PTS).

Anaplastic Thyroid Cancer

ATC has an annual incidence of one to two cases per million people [5] and comprises 0.9% of all thyroid cancers [3]. Although this only amounts to what the National Cancer Institute estimates to be 600 new cases in 2016, it is among the most aggressive malignancies, contributing to 14–50% of intra-yearly thyroid deaths [3,5]. ATC can arise *de novo* or from a well-differentiated cancer, which is estimated to co-exist in half of patients with this malignancy [6,7]. The

Author for correspondence: Y. Ducic, Department of Head and Neck Surgery, Otolaryngology and Facial Plastic Surgery Associates, Dallas-Fort Worth, TX, USA.

E-mail address: yducic@sbcglobal.net (Y. Ducic).

<http://dx.doi.org/10.1016/j.clon.2017.01.041>

0936-6555/© 2017 The Royal College of Radiologists. Published by Elsevier Ltd. All rights reserved.

average age at diagnosis is 71 years [8], with a 3:2 female:male ratio [9]. Patients with ATC most commonly present with an enlarging neck mass and associated pain, dysphonia or dyspnoea that is progressive in nature [1].

Pure ATC carries an incredibly poor prognosis, with a median survival time of 6 months [10]. Patients with small foci of ATC within a larger well-differentiated tumour carry substantially higher 5 year survival rates, reported as high as 81% versus 14% for those with pure ATC [11,12]. Half of patients with ATC have distant metastases at presentation and less than 10% present solely with intrathyroidal disease [8,9,13]. The natural history of ATC often results in death secondary to asphyxiation or vessel compression [1]. With airway management via tracheostomy, death more commonly results from respiratory insufficiency caused by pulmonary metastases [14].

When evaluating any type of enlarging neck mass, airway stability is critical and should be determined before any further work-up. Computed tomography and rarely magnetic resonance imaging (MRI) are indicated to characterise the mass. Fine-needle aspiration (FNA) is carried out in attempt to ascertain a tissue diagnosis. In our combined experience, larger samples from core or surgical biopsy are often needed to rule out lymphoma [1]. Nevertheless, FNA can be sufficient for diagnosis with the help of an expert cytopathologist and should always be attempted before proceeding to more invasive measures. Patients must be monitored after biopsy due to the risk of tumour bleeding that may cause mass expansion and exacerbate airway compression.

Microscopic tissue examination shows undifferentiated spindle, giant or squamoid cells with areas of necrosis [10]. After diagnosis, staging is determined by measuring tumour burden with 18F-FDG positron emission tomography/computed tomography (PET/CT) scan before a treatment plan may be devised [15]. Lesions confined to the thyroid gland are classified as stage IVA. Stage IVB characterises lesions that have grown outside of the thyroid capsule without distal spread; stage IVC is reserved for any lesion with associated distant metastases [16].

The American Thyroid Association (ATA) guidelines on the management of ATC serve as a thorough resource for clinicians [17]. This review provides an overview of those principles and discusses recent publications and advances in disease management. Before any treatment decisions are made, a fundamental understanding of the patient's goals of care must be obtained. Patients should be encouraged to draft advance directives with their families early in the disease process.

Treatment options include a combination of radiation, surgery or chemotherapy. The hallmark of treatment for stage IVA and resectable cases of stage IVb disease is surgical excision of gross disease and lymph node dissection with subsequent intensity-modulated radiation therapy. Adjuvant systemic chemotherapy should be considered on a case-by-case basis. However, no consensus exists on its use for locoregional disease [17]. For patients with unresectable local disease, radiation with or without systemic chemotherapy is recommended and surgery should only be considered if the lesion later becomes resectable.

Metastatic disease is treated with combination chemotherapy and radiation therapy. In accordance with the ATA guidelines, any patient with a poor performance status or unresectable disease should be offered the option of supportive palliative care in lieu of aggressive treatment. Patients with higher stage disease commonly require tracheostomy and nutritional support with a gastrostomy tube [1,6]. However, routine tracheostomy is not advocated without a frank discussion regarding changes to quality of life [8,18]. No standard chemotherapeutic regimen exists, although the ATA recommends several combinations of paclitaxel, docetaxel, carboplatin and doxorubicin [17]. In recent studies, there have been more promising results with new drug modalities. The combination of carfilzomab, a proteasome inhibitor, and CUDC-101, a histone deacetylase, has been shown to induce apoptosis in ATC cells [19]. Another recent study has shown positive results through the use of doxorubicin nanospheres combined with extracorporeal shock wave therapy [20].

Although the ATA guidelines advise against tumour debulking for unresectable disease, the role of surgery in patients with tumour extension beyond the thyroid gland has become controversial [15]. Disease extending significantly beyond the thyroid gland has typically represented unresectable malignancy, but the determinants of this classification are not entirely clear [21–26]. The positive predictive value and accuracy for computed tomography scans correctly staging disease when compared with post-surgical pathology reports has not been thoroughly studied and requires an experienced surgeon to decipher tumour scans and their operative correlates [27–29]. A recent study by Brown and Ducic [30] seemingly supports this notion, showing longer-term survival in a cohort of select patients with stage IVB disease after undergoing variable resections involving the larynx, trachea and oesophagus, as dictated by the extent of disease. In these patients, without disease extension beyond the carotid arteries, who underwent surgery and adjuvant radiation, 50% had long-term disease-free survival ranging from 9 months to 8 years [30]. Other recent studies support the use of aggressive multimodality treatment including surgery and curative radiation therapy [31,32]. On multivariate analysis of factors predictive of survival, Mohebati *et al.* [32] showed hazard ratios less than 0.5 for patients receiving multimodality treatment with surgery and those whose surgery resulted in complete or near complete resection with only residual microscopic disease.

Ongoing research attempts to further characterise the mutations that enable the development of ATC, including the importance of: TP53 (50–80%), CTNNB1 (5–60%) and AKT1 (5–10%), which are unique to ATC [33,34]. The lack of effectiveness of current chemotherapeutic regimens is driving the search for more targeted therapies. Within the past 5 years, multiple trials have tested the efficacy of newly developed drugs, which are summarised in Table 1. Despite minimal improvements in outcomes, none has proved to be a breakthrough treatment. The most recent of these newly tested medications, fosbretabulin, was studied in the 2014 FACT Trial (Fosbretabulin in Anaplastic Cancer of the

Table 1
Summary of recent clinical trials for the treatment of anaplastic thyroid cancer

Reference	Intervention	Outcomes
[35]	Fosbretabulin (tubulin binding vascular disrupting agent)+CP	<ul style="list-style-type: none"> •80 patients •Fosbretabulin/CP arm: $n = 55$ <ul style="list-style-type: none"> ○ Median survival time = 5.2 months ○ Hazard ratio 0.73 •CP arm: $n = 25$ <ul style="list-style-type: none"> ○ Median survival time = 4.0 months ($P = 0.22$) •No significant difference in PFS between the two arms
[36]	Sorafenib (tyrosine kinase inhibitor)	<ul style="list-style-type: none"> •20 patients •Median PFS = 1.9 months •Median survival time = 3.9 months
[37]	Efatutazone (PPAR- γ agonist)+paclitaxel	<ul style="list-style-type: none"> •15 patients •0.3 mg Efaturazone trial arm: <ul style="list-style-type: none"> ○ Median PFS = 68 days ○ Median survival time = 138 days
[38]	Pazopanib (kinase+VEGFR inhibitor)	<ul style="list-style-type: none"> •16 patients •No confirmed RECIST responses •Median PFS = 62 days •Median survival time = 111 days

VEGFR, vascular endothelial growth factor receptor; CP, carboplatin/paclitaxel; PFS, progression-free survival; RECIST, Response Evaluation Criteria in Solid Tumors.

Thyroid), but was not found to have a significant effect on progression-free survival [35]. However, it is important to note that the control arm consisting of carboplatin AUC 6 and paclitaxel 200 mg/m² was previously untested and showed higher than expected activity, making it difficult to make an informed conclusion about the utility of the drug. At the time of this review, 19 active studies registered through ClinicalTrials.gov are investigating various treatment modalities.

Pure ATC has a very poor prognosis and is most often fatal. ATC that arises from a differentiated cancer carries an improved prognosis, with survival rates dependent on the proportion of undifferentiated cells [12]. Long-term survival is associated with resectability of locoregional cancer, localised intrathyroidal disease, coexistence with differentiated disease, and the absence of distal metastases [12,39–41]. Treatment of this condition requires a multidisciplinary team with a patient-centred approach to carefully assess and treat primary disease extension, metastatic disease burden and airway.

Medullary Thyroid Cancer

MTC arises from calcitonin-producing parafollicular c-cells and comprises 2.1% of thyroid malignancies. It is increasing in frequency, with a 2.3% average annual increase in incidence between 1992 and 2012 [1,3]. The average age at diagnosis is 50, with 30% of patients under age 40 years [42]. Women are more commonly affected than men, with a ratio of 3:2 [42].

There are two pathways that lead to the development of MTC from parafollicular c-cells. About 25% of cases are

hereditary in nature and are associated with the autosomal dominant RET proto-oncogene, which is the driving mutation in the multiple endocrine neoplasia (MEN) 2A and 2B syndromes. These cancers are more likely to be multifocal and bilateral because all cells in the thyroid contain the dominant RET oncogene [43–49]. The remaining 75% of cases are non-hereditary, occurring due to a single sporadic mutation that results in a unilateral lesion [50,51]. About half of these sporadic mutations also occur in the RET gene, which is associated with more aggressive disease and a worse prognosis [46,52].

Patients with a known family history are often diagnosed in the preclinical phase with DNA testing. MEN2A typically occurs in the third decade of life and is far more common than MEN2B, which only accounts for 2% of all MTC and occurs during the first decade of life [53]. The MEN2A syndrome is associated with pheochromocytoma and hyperparathyroidism, whereas MEN2B is associated with mucosal neuromas, marfanoid habitus and pheochromocytoma [43,44,54,55].

Non-hereditary or MEN2 index patients most commonly present with a painless thyroid nodule, often accompanied by palpable cervical adenopathy [50,56]. Because parafollicular c-cells are neuroendocrine cells in origin, they may produce carcinoembryonic antigen (CEA), prostaglandin and serotonin. Excess production of these hormones can cause systemic symptoms, such as diarrhoea or flushing [13,50]. In a retrospective study evaluating 1252 patients with MTC, Graff-Baker *et al.* [57] found that 48% of patients do not have extrathyroidal disease on diagnosis. Thirty-five per cent exhibited regional spread at diagnosis, whereas another 13% were found to have distal metastases. MTC most frequently metastasises to the mediastinum, liver, bone and lung [58].

Diagnosis of MTC involves ultrasound and FNA of a thyroid nodule to obtain tissue diagnosis [15]. Elevated levels of serum calcitonin >60 pg/ml are suggestive of MTC, although significant controversy exists regarding screening cut-off values [59,60]. Histologically, MTC is composed of heterogeneous infiltrating cells and classically contains amyloid deposits of polymerised calcitonin, although this is not always present [61]. Both calcitonin and CEA levels correlate with tumour burden and should be used to guide work-up and therapy [45,62]. Thyroid and neck ultrasound are indicated for staging purposes [15]. Calcitonin levels >500 pg/ml warrant further screening for metastatic disease to the mediastinum and other body sites via computed tomography of the chest and MRI of the liver [15,45,63]. Routine 18F-FDG PET scanning is not indicated because of poor sensitivity for MTC, but 18F-DOPA can be used as a radiotracer [64].

All patients diagnosed with MTC should be screened for germline RET mutations before starting any medical or surgical treatment. In the presence of a positive germline mutation or in whom genetic testing is not possible, screening for hyperparathyroidism and pheochromocytoma should be carried out to prevent intraoperative complications [1,50].

The treatment for MTC includes total thyroidectomy and central neck lymph node dissection. Prophylactic ipsilateral dissection of levels II–V should be strongly considered in the presence of central neck disease due to the high rates (>77%) of ipsilateral occult nodal involvement [65]. For patients with elevated calcitonin or clinically evident lateral neck disease, ipsilateral lymph node dissection of levels II–VI should be carried out with consideration of bilateral neck dissection [45]. The incidence of contralateral node involvement is directly proportional to the extent of central node disease, reaching 77% when 10 or more central nodes are involved [65]. For patients with known MEN, prophylactic thyroidectomy is indicated by age 5 years for MEN2A and by age 1 year for MEN2b [15]. External beam radiation is indicated only for unresectable margins or rarely as adjuvant therapy for residual disease [15]. Postoperative

monitoring of calcitonin and CEA play a crucial role to evaluate for persistent or recurrent disease. The ‘doubling time’ of calcitonin, meaning the time required for serum calcitonin levels to double, should be calculated for its valuable prognostic information. A doubling time of greater than 6 months is associated with a 5 year survival of 92%, whereas a doubling time less than 6 months is associated with a 5 year survival of 25% [66]. In accordance with the National Comprehensive Cancer Network (NCCN) guidelines, serum calcitonin greater than 150 pg/ml suggests residual or recurrent disease and warrants further imaging of the neck, chest and abdomen [15,60,67].

Recurrent or persistent MTC is best treated with surgery. However, cases of severely advanced or otherwise unresectable disease can be treated with radiation and systemic therapy. In such cases, single-agent targeted chemotherapy against RET and vascular endothelial growth factor receptor (VEGFR) tyrosine kinases with cabozantinib or vandetanib offers the best prognosis, particularly for patients whose cancers carry a RET mutation [45,68–70]. Recent phase III clinical trials show significantly improved progression-free survival rates with hazard ratios of 0.28 and 0.46 for cabozantinib and vandetanib, respectively (Table 2). Because these studies used different enrolment criteria, it is not clear if one of these medications is associated with superior outcomes. Although both agents are Food and Drug Administration approved for the treatment of advanced disease, the cabozantinib trial shows more convincing evidence for effectiveness in patients without a RET mutation.

Cytotoxic agents are not recommended as a first-line treatment due to response rates lower than 20% [45,68,71–73]. Newer drugs continue to be investigated. Lenvatinib, a tyrosine kinase inhibitor, was recently shown to have modest responses in phase II trials [74] and there are currently 20 active trials registered on ClinicalTrials.gov in search of more promising therapies.

The overall prognosis of MTC is related to age and disease stage at diagnosis. MTC is a serious and potentially lethal condition, but generally carries a favourable prognosis, especially for those with early stage disease who achieve

Table 2
Summary of phase III trials of tyrosine kinase inhibitors for the treatment of medullary thyroid cancer (MTC)

Reference	Inclusion criteria	Intervention	Outcomes
EXAM Trial [69]	Progressive unresectable locally advanced or metastatic MTC	Cabozantinib 140 mg daily versus placebo	<p>Cabozantinib arm: $n=219$ patients</p> <ul style="list-style-type: none"> • Median PFS = 11.2 months • Hazard ratio = 0.28 • Responses observed in patients without RET mutations <p>Placebo arm: $n = 111$ patients</p> <ul style="list-style-type: none"> • Median PFS = 4 months
ZETA Trial [70]	Stable or progressive unresectable locally advanced or metastatic MTC	Vandetanib 300 mg daily versus placebo	<p>Vandetanib arm: $n = 231$ patients</p> <ul style="list-style-type: none"> • Estimated median PFS = 30.5 months • Hazard ratio = 0.46 <p>Placebo arm: $n = 100$ patients</p> <ul style="list-style-type: none"> • Median PFS = 19.3 months

PFS, progression-free survival

complete remission. Ten year survival for all MTC ranges from 20.7% in stage IV disease to 100% in stage I cancers [75–77]. The key to successful treatment of such patients is early diagnosis with appropriate surgical intervention followed by careful postoperative monitoring.

Primary Thyroid Lymphoma

PTL comprises 1–5% of all thyroid malignancies [78,79]. The average age at diagnosis is 66 years old [57] and the strongest risk factor for PTL is Hashimoto's thyroiditis, with a reported 67–80-fold increased risk [80,81]. Eighty-seven per cent of patients diagnosed with PTL have a history of Hashimoto's thyroiditis [82], making it significantly more common in women [57].

PTL presents as a painless enlarging neck mass without constitutional symptoms [83]. Ultrasound and FDG PET/CT are the most useful imaging modalities in diagnosis [84,85]. PTL usually presents with firm and diffuse thyroid enlargement, which feels more rubbery than rock hard as with ATC; however, both of these pathologies share physical examination findings, gland palpation findings and symptoms.

FNA frequently yields inconclusive information and as such, core or incisional biopsy is often required [1,86–88]. In a large retrospective review, Sharma *et al.* [86] showed that 100% of patients who initially underwent FNA required additional tissue to guide treatment. Nearly one-third of patients ultimately treated for thyroid lymphoma had false-negative FNAs, indicating the importance of pursuing an

aggressive work-up when concerning imaging or physical examination findings are present. However, the addition of flow cytometry and immunohistochemistry to FNA significantly increases its sensitivity and specificity [89].

PTL can be broken down into multiple subtypes, illustrated in Figure 1. Most cases of PTL arise from B-cells that form non-Hodgkin's lymphomas. However, T-cell lymphomas, plasmacytomas and Hodgkin's lymphomas have been reported, but are exceedingly rare [88,90]. The three main subtypes of B-cell non-Hodgkin's lymphoma are mucosal-associated lymphoid tissue (MALT) lymphoma, diffuse large B-cell lymphoma (DLBCL) and a mixed variant [82]. MALT lymphoma is generally low grade with indolent growth, whereas DLBCL is more aggressive. The mixed variant behaves more similarly to DLBCL [79,88,91–93].

PTL is treated with chemoradiation therapy. Surgery is reserved for early stage MALT or for patients with compressive symptoms [83,94]. Some patients with neglected advanced primary disease develop severe compressive symptoms of the oesophagus or trachea and may require tracheostomy or gastrostomy tube placement temporarily while beginning systemic therapy. Specialised airway management with experienced head and neck and anaesthesia teams is necessary in these specific patients and caution should be taken in any gastrostomy tube referral without airway evaluation. The chemotherapeutic regimen most often used is CHOP, which consists of cyclophosphamide, hydroxydoxorubicin, vincristine and prednisone with rituximab recently added for patients with DLBCL [95–97]. Rituximab is a monoclonal antibody against CD20, thereby offering specificity to B-cells and a much

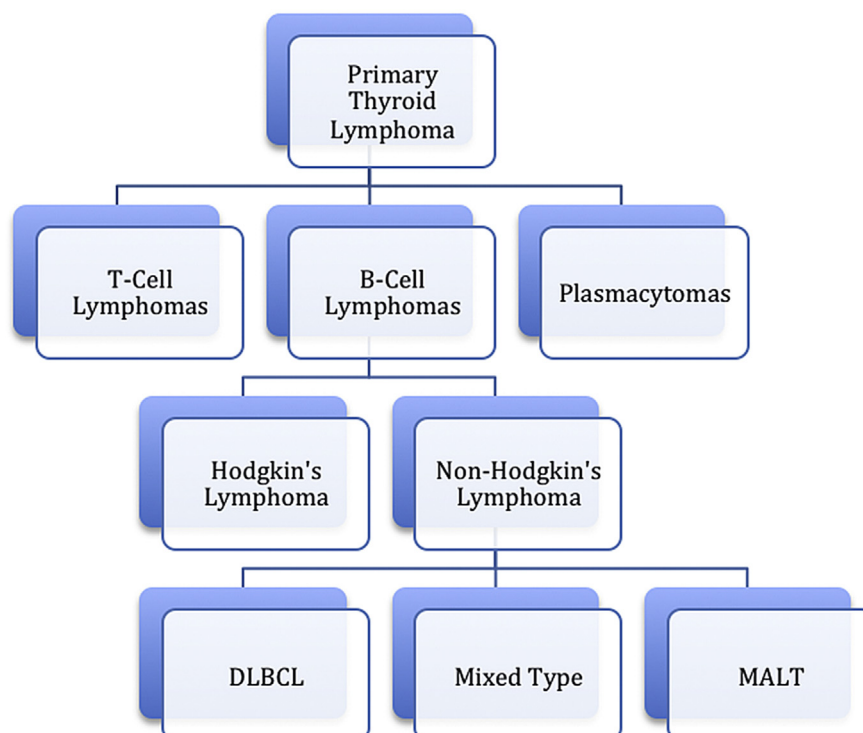


Fig 1. Primary thyroid lymphoma subtypes.

more targeted treatment. The addition of rituximab has been found to substantially decrease relapse rates from 21% to 7% when added to the standard CHOP regimen [97].

The prognosis for PTL is correlated with its stage. Staging is based on the degree of disease extension from the thyroid gland. Stage IE disease is localised to the thyroid gland; stage IIE disease is localised to the gland but also involves regional lymph nodes; stage IIIE disease involves spread to lymph nodes on both sides of the diaphragm; stage IVE disease has spread to distant sites of the body [57]. Regardless of PTL subtype, early stage disease has a favourable prognosis, with a 5 year survival rate >85% for stage IE PTL [57,82]. Higher stages have poorer outcomes, with a 64% 5 year survival rate for patients with stage IIIE and IVE disease [57].

Despite the potential lethality of PTL, early stage disease carries a favourable prognosis. This emphasises the importance of obtaining a timely diagnosis with flow cytometry by maintaining a high suspicion for lymphoma, especially in patients with Hashimoto's thyroiditis.

Primary Thyroid Sarcoma

PTS is an exceedingly rare condition that comprises less than 1.5% of all thyroid malignancies and mostly affects patients aged 60–80 years old [98–100]. PTS encompasses many subtypes of thyroid sarcoma, including angiosarcoma, hemangioendothelioma [101], fibrosarcoma [102], leiomyosarcoma [103] and fibrous histiocytoma, among others [104,105]. This cancer mimics distant tissue, making it important to first rule out metastatic disease involving the thyroid before establishing a diagnosis of a primary thyroid malignancy.

The most significant risk factor for PTS is the increased risk of angiosarcoma associated with iodine-deficient goiter. A substantially higher incidence of disease is found in the European Alpine region, where about 16% of thyroid malignancies are angiosarcoma [106], but occurrence outside of this area is exceedingly rare [107]. Nevertheless, most other patients with PTS do not possess a specific risk factor for this entity.

PTS presents as a thyroid nodule without any additional symptoms unless the disease is advanced [98]. The diagnostic algorithm involves thyroid ultrasound followed by FNA. On ultrasound, these lesions exhibit a non-specific hypo-hyperechoic pattern [108]. It is important for the pathology team to recognise that certain subsets of sarcoma, especially angiosarcoma, can often have similar pathological findings to other thyroid malignancies [109]. In addition to histological evaluation, immunohistochemistry plays an important role in diagnosis, by staining for CD31, which is the most sensitive and specific marker as well as CD34 and factor VIII [110]. These tumours generally stain negative for pancytokeratin and thyroglobulin, although there is a subset of epithelioid angiosarcomas that are cytokeratin positive [107].

Although there is no consensus within the literature on a comprehensive treatment plan for patients with PTS, surgery plays a central role in nearly all cases. Adjuvant

therapies have not been specifically studied, but there is an emerging body of literature regarding treatment of head and neck soft tissue sarcomas, which encompasses PTS. Providers may extrapolate from these studies, but it is not clear if PTS behaves identically to other head and neck sarcomas. The NCCN guidelines on head and neck sarcomas recommend surgical management as primary therapy in cases with resectable disease and an anticipated 'acceptable functional outcome'. They recommend chemoradiation therapy for patients where resection has inadequate margins. For patients with unresectable disease or unacceptable functional outcomes with surgery, chemoradiation therapy becomes the mainstay of treatment with subsequent surgical intervention if the tumour becomes resectable [111,112]. As with any sarcoma, negative margins with surgery are critically important. Specifically, a challenge to head and neck surgeons is obtaining the recommended 1–4 cm margin clearance around the cancer to minimise local recurrence rates. Surgeons must consider the balance between local recurrence rates and functional outcomes after reconstruction. Pre-surgical chemotherapy or radiation should be considered in each individual case where there is doubt regarding the ability to obtain negative margins. The whole body sarcoma literature has not fully parsed out the role of multi-modality treatment order, specifically in regards to optimising margin control and local recurrence rates; however, it is clear that negative margins are the most predictive factor in controlling local disease and sarcomas overall do volumetrically respond to pre-surgical treatment. Future studies are needed to address the optimisation of margin control with multi-modality treatment.

In the largest review to date, Surov *et al.* [108] evaluated 142 cases of PTS. They reported that 70% of patients presented without distal metastases, but leiomyosarcoma and angiosarcoma were more likely to be metastatic on presentation, most often involving the lung. In their review, 75 patients were treated with surgery alone, whereas 53 had surgery with adjuvant chemoradiation. Only seven patients were treated without surgical intervention.

Limited information is known regarding the overall prognosis or 5 year survival of patients with PTS, which probably varies with each subtype. One study reported a 33% 5 year survival for angiosarcoma and noted that patients present at a late stage [106]. By contrast, the 4 year survival rate for all patients with general head and neck soft tissue sarcoma is 72%, but these data are not limited specifically to patients with thyroid sarcoma [113]. Surgery plays a significant role in the management of this malignancy, but given the paucity of research and the lack of consensus on systemic therapy, patients who carry this diagnosis should be treated aggressively by experienced multidisciplinary physician teams.

Conclusion

ATC, MTC, PTL and PTS are rare tumours that make up a small proportion of all thyroid malignancies. Most providers

do not have extensive experience treating these conditions, especially in multidisciplinary coordination, and the guiding literature available is limited due to low disease prevalence. Despite current treatments, these aggressive malignancies result in significant morbidity and mortality. As such, clinical trial investigations are of vital importance in search of future advancements. It is the responsibility of providers to establish a timely diagnosis for suspicious thyroid nodules in order to quickly initiate appropriate treatment to optimise outcomes for these rare cancers.

References

- [1] Lai SY, Mandel SJ, Weber RS. *Management of thyroid neoplasms. Cummings otolaryngology – head and neck surgery*. Amsterdam: Elsevier; 2010. p. 1750–1772.
- [2] LiVolsi VA. *Pathology of thyroid tumors*. Philadelphia: Saunders; 1987.
- [3] Mao Y, Xing M. Recent incidences and differential trends of thyroid cancer in the USA. *Endocr Relat Cancer* 2016;23:313–322.
- [4] Kitahara CM, Sosa JA. The changing incidence of thyroid cancer. *Nature Reviews Endocrinol* 2016 Nov;12(11):646–653.
- [5] Nagaiah G, Hossain A, Mooney CJ, et al. Anaplastic thyroid cancer: a review of epidemiology, pathogenesis, and treatment. *J Oncol* 2011;2011:1–13.
- [6] Neff RL, Farrar WB, Kloos RT, et al. Anaplastic thyroid cancer. *Endocrinol Metab Clin North Am* 2008;37:525–538.
- [7] Haddad RI, Lydiatt WM, Ball DW, et al. Anaplastic thyroid carcinoma, version 2.2015. *J Natl Compr Canc Netw* 2015;13:1140–1150.
- [8] Kebebew E, Greenspan FS, Clark OH, et al. Anaplastic thyroid carcinoma. *Cancer* 2005;103:1330–1335.
- [9] Glaser SM, Mandish SF, Gill BS, et al. Anaplastic thyroid cancer: prognostic factors, patterns of care, and overall survival. *Head Neck* 2016;38(Suppl. 1):E2083–E2090.
- [10] Are C, Shaha AR. Anaplastic thyroid carcinoma: biology, pathogenesis, prognostic factors, and treatment approaches. *Ann Surg Oncol* 2006;13:453–464.
- [11] Akaishi J, Sugino K, Kitagawa W, et al. Prognostic factors and treatment outcomes of 100 cases of anaplastic thyroid carcinoma. *Thyroid* 2011;21:1183–1189.
- [12] Lee DY, Won JK, Lee SH, et al. Changes of clinicopathologic characteristics and survival outcomes of anaplastic and poorly differentiated thyroid carcinoma. *Thyroid* 2016;26:404–413.
- [13] Demeter JG, De Jong SA, Lawrence AM, et al. Anaplastic thyroid carcinoma: risk factors and outcome. *Surgery* 1991;110:956–961. discussion 961–963.
- [14] Kitamura Y, Shimizu K, Nagahama M, et al. Immediate causes of death in thyroid carcinoma: clinicopathological analysis of 161 fatal cases. *J Clin Endocrinol Metab* 1999;84:4043–4049.
- [15] Edge SB, American Joint Committee on Cancer. *AJCC cancer staging manual*, 7th ed. New York: Springer; 2010.
- [16] American Joint Committee on Cancer. *How is thyroid cancer staged?* 2016.
- [17] Smallridge RC, Ain KB, Asa SL, et al. American Thyroid Association guidelines for management of patients with anaplastic thyroid cancer. *Thyroid* 2012;22:1104–1139.
- [18] Shaha AR. Airway management in anaplastic thyroid carcinoma. *Laryngoscope* 2008;118:1195–1198.
- [19] Zhang L, Boufraquech M, Lake R, et al. Carfilzomib potentiates CUDC-101-induced apoptosis in anaplastic thyroid cancer. *Oncotarget* 2016.
- [20] Marano F, Argenziano M, Frairia R, et al. Doxorubicin-loaded nanobubbles combined with extracorporeal shock waves: basis for a new drug delivery tool in anaplastic thyroid cancer. *Thyroid* 2016;26:705–716.
- [21] McIver B, Hay ID, Giuffrida DF, et al. Anaplastic thyroid carcinoma: a 50-year experience at a single institution. *Surgery* 2001;130:1028–1034.
- [22] Venkatesh YSS, Ordóñez NG, Schultz PN, et al. Anaplastic carcinoma of the thyroid: a clinicopathologic study of 121 cases. *Cancer* 1990;66:321–330.
- [23] Haigh PI. Anaplastic thyroid carcinoma. *Curr Treat Options Oncol* 2000;1:353–357.
- [24] Grant CS, Thompson G. Anaplastic thyroid carcinoma: hope on the horizon? *Surgery* 2011;150:1220–1221.
- [25] Passler C, Scheuba C, Prager G, et al. Anaplastic (undifferentiated) thyroid carcinoma (ATC). *Langenbeck's Arch Surg* 1999;384:284–293.
- [26] Cobin RH, Gharib H, Bergman DA, et al. AAACE/AAES medical/surgical guidelines for clinical practice: management of thyroid carcinoma. American Association of Clinical Endocrinologists. American College of Endocrinology. *Endocr Pract* 2001;7:202–220.
- [27] Biron VL, O'Connell DA, Seikaly H. The impact of clinical versus pathological staging in oral cavity carcinoma – a multi-institutional analysis of survival. *J Otolaryngol Head Neck Surg* 2013;42:28.
- [28] Haughey BH, Sinha P. Prognostic factors and survival unique to surgically treated p16+ oropharyngeal cancer. *Laryngoscope* 2012;122(Suppl. 2):S13–S33.
- [29] Koch WM, Ridge JA, Forastiere A, et al. Comparison of clinical and pathological staging in head and neck squamous cell carcinoma: results from Intergroup Study ECOG 4393/RTOG 9614. *Arch Otolaryngol Head Neck Surg* 2009;135:851–858.
- [30] Brown RF, Ducic Y. Aggressive surgical resection of anaplastic thyroid carcinoma may provide long-term survival in selected patients. *Otolaryngol Head Neck Surg* 2013;148:564–571.
- [31] Nachalon Y, Stern-Shavit S, Bachar G, et al. Aggressive palliation and survival in anaplastic thyroid carcinoma. *JAMA Otolaryngol Head Neck Surg* 2015;141:1128–1132.
- [32] Mohebbati A, Dilorenzo M, Palmer F, et al. Anaplastic thyroid carcinoma: a 25-year single-institution experience. *Ann Surg Oncol* 2014;21:1665–1670.
- [33] Ranganath R, Shah MA, Shah AR. Anaplastic thyroid cancer. *Curr Opin Endocrinol Diabetes Obesity* 2015;22:387–391.
- [34] Pinto N, Black M, Patel K, et al. Genomically driven precision medicine to improve outcomes in anaplastic thyroid cancer. *J Oncol* 2014;2014:1–7.
- [35] Sosa JA, Elisei R, Jarzab B, et al. Randomized safety and efficacy study of fosbretabulin with paclitaxel/carboplatin against anaplastic thyroid carcinoma. *Thyroid* 2014;24:232–240.
- [36] Savvides P, Nagaiah G, Lavertu P, et al. Phase II trial of sorafenib in patients with advanced anaplastic carcinoma of the thyroid. *Thyroid* 2013;23:600–604.
- [37] Smallridge RC, Copland JA, Brose MS, et al. Efatutazone, an oral PPAR- γ agonist, in combination with paclitaxel in anaplastic thyroid cancer: results of a multicenter phase 1 trial. *J Clin Endocrinol Metab* 2013;98:2392–2400.
- [38] Bible KC, Suman VJ, Menefee ME, et al. A multiinstitutional phase 2 trial of pazopanib monotherapy in advanced anaplastic thyroid cancer. *J Clin Endocrinol Metab* 2012;97:3179–3184.
- [39] Voutilainen PE, Multanen M, Haapiainen RK, et al. Anaplastic thyroid carcinoma survival. *World J Surg* 1999;23:975–979.

- [40] Hundahl SA, Fleming ID, Fremgen AM, et al. A National Cancer Data Base report on 53,856 cases of thyroid carcinoma treated in the U.S., 1985–1995. *Cancer* 1998;83:2638–2648.
- [41] Tan RK, Finley RK, Driscoll D, et al. Anaplastic carcinoma of the thyroid: a 24-year experience. *Head Neck* 1995;17:41–48.
- [42] Roman S, Lin R, Sosa JA. Prognosis of medullary thyroid carcinoma: demographic, clinical, and pathologic predictors of survival in 1252 cases. *Cancer* 2006;107:2134–2142.
- [43] DeLellis RA. Multiple endocrine neoplasia syndromes revisited. Clinical, morphologic, and molecular features. *Lab Invest* 1995;72:494–505.
- [44] Raue F, Frank-Raue K. *Multiple endocrine neoplasia type 2. Encyclopedia of life sciences*. Oxford: Wiley-Blackwell; 2010.
- [45] Wells SA, Asa SL, Dralle H, et al. Revised American Thyroid Association guidelines for the management of medullary thyroid carcinoma. *Thyroid* 2015;25:567–610.
- [46] Elisei R, Cosci B, Romei C, et al. Prognostic significance of somatic RET oncogene mutations in sporadic medullary thyroid cancer: a 10-year follow-up study. *J Clin Endocrinol Metab* 2008;93:682–687.
- [47] Moura MM, Cavaco BM, Pinto AE, et al. High prevalence of RAS mutations in RET-negative sporadic medullary thyroid carcinomas. *J Clin Endocrinol Metab* 2011;96:E863–E868.
- [48] Boichard A, Croux L, Al Ghuzlan A, et al. Somatic RAS mutations occur in a large proportion of sporadic RET-negative medullary thyroid carcinomas and extend to a previously unidentified exon. *J Clin Endocrinol Metab* 2012;97:E2031–E2035.
- [49] Agrawal N, Jiao Y, Sausen M, et al. Exomic sequencing of medullary thyroid cancer reveals dominant and mutually exclusive oncogenic mutations in RET and RAS. *J Clin Endocrinol Metab* 2013;98:E364–E369.
- [50] Hadoux J, Pacini F, Tuttle RM, et al. Management of advanced medullary thyroid cancer. *Lancet Diabetes Endocrinol* 2016;4:64–71.
- [51] Chong GC, Beahrs OH, Sizemore GW, et al. Medullary carcinoma of the thyroid gland. *Cancer* 1975;35:695–704.
- [52] Moura MM, Cavaco BM, Pinto AE, et al. Correlation of RET somatic mutations with clinicopathological features in sporadic medullary thyroid carcinomas. *Br J Cancer* 2009;100:1777–1783.
- [53] Raue F, Frank-Raue K. Epidemiology and clinical presentation of medullary thyroid carcinoma. *Recent Results Cancer Res* 2015;204:61–90.
- [54] Moley JF. Medullary thyroid cancer. *Surg Clin North Am* 1995;75:405–420.
- [55] Goodfellow PJ, Wells SA. RET gene and its implications for cancer. *J Natl Cancer Inst* 1995;87:1515–1523.
- [56] Scollo C, Baudin E, Travagli JP, et al. Rationale for central and bilateral lymph node dissection in sporadic and hereditary medullary thyroid cancer. *J Clin Endocrinol Metab* 2003;88:2070–2075.
- [57] Graff-Baker A, Roman SA, Thomas DC, et al. Prognosis of primary thyroid lymphoma: demographic, clinical, and pathologic predictors of survival in 1,408 cases. *Surgery* 2009;146:1105–1115.
- [58] Ellenhorn JD, Shah JP, Brennan MF. Impact of therapeutic regional lymph node dissection for medullary carcinoma of the thyroid gland. *Surgery* 1993;114:1078–1081. discussion 1081–1082.
- [59] Bae YJ, Schaab M, Kratzsch J. Calcitonin as biomarker for the medullary thyroid carcinoma. *Recent Results Cancer Res* 2015;204:117–137.
- [60] Machens A, Schneyer U, Holzhausen H-J, et al. Prospects of remission in medullary thyroid carcinoma according to basal calcitonin level. *J Clin Endocrinol Metab* 2005;90:2029–2034.
- [61] Stepanas AV, Samaan NA, Hill CS, et al. Medullary thyroid carcinoma. Importance of serial serum calcitonin measurement. *Cancer* 1979;43:825–837.
- [62] Meijer JA, le Cessie S, van den Hout WB, et al. Calcitonin and carcinoembryonic antigen doubling times as prognostic factors in medullary thyroid carcinoma: a structured meta-analysis. *Clin Endocrinol* 2010;72:534–542.
- [63] Machens A, Dralle H. Biomarker-based risk stratification for previously untreated medullary thyroid cancer. *J Clin Endocrinol Metab* 2010;95:2655–2663.
- [64] Beheshti M, Pöcher S, Vali R, et al. The value of 18F-DOPA PET-CT in patients with medullary thyroid carcinoma: comparison with 18F-FDG PET-CT. *Eur Radiol* 2009;19:1425–1434.
- [65] Machens A, Hauptmann S, Dralle H. Prediction of lateral lymph node metastases in medullary thyroid cancer. *Br J Surg* 2008;95:586–591.
- [66] Barbet J, Campion L, Kraeber-Bodéré F, et al. Prognostic impact of serum calcitonin and carcinoembryonic antigen doubling-times in patients with medullary thyroid carcinoma. *J Clin Endocrinol Metab* 2005;90:6077–6084.
- [67] Laure Giraudet A, Al Ghulzan A, Auperin A, et al. Progression of medullary thyroid carcinoma: assessment with calcitonin and carcinoembryonic antigen doubling times. *Eur J Endocrinol* 2008;158:239–246.
- [68] Zhu H-g, Zhao J-y, Zhang R, et al. New agent to treat advanced or metastasized thyroid cancer, its efficacy, safety, and mechanism. *Thoracic Cancer* 2015;6:539–543.
- [69] Elisei R, Schlumberger MJ, Müller SP, et al. Cabozantinib in progressive medullary thyroid cancer. *J Clin Oncol* 2013;31:3639–3646.
- [70] Wells SA, Robinson BG, Gagel RF, et al. Vandetanib in patients with locally advanced or metastatic medullary thyroid cancer: a randomized, double-blind phase III trial. *J Clin Oncol* 2011;30:134–141.
- [71] Shimaoka K, Schoenfeld DA, Dewys WD, et al. A randomized trial of doxorubicin versus doxorubicin plus cisplatin in patients with advanced thyroid carcinoma. *Cancer* 1985;56:2155–2160.
- [72] Williams SD, Birch R, Einhorn LH. Phase II evaluation of doxorubicin plus cisplatin in advanced thyroid cancer: a Southeastern Cancer Study Group Trial. *Cancer Treat Rep* 1986;70:405–407.
- [73] Schlumberger M, Abdelmoumene N, Delisle MJ, et al. Treatment of advanced medullary thyroid cancer with an alternating combination of 5 FU-streptozocin and 5 FU-dacarbazine. *Br J Cancer* 1995;71:363–365.
- [74] Schlumberger M, Jarzab B, Cabanillas ME, et al. A phase II trial of the multitargeted tyrosine kinase inhibitor lenvatinib (E7080) in advanced medullary thyroid cancer. *Clin Cancer Res* 2016;22:44–53.
- [75] Modigliani E, Cohen R, Campos J-M, et al. Prognostic factors for survival and for biochemical cure in medullary thyroid carcinoma: results in 899 patients. *Clin Endocrinol* 1998;48:265–273.
- [76] Rendl G, Manzl M, Hitzl W, et al. Long-term prognosis of medullary thyroid carcinoma. *Clin Endocrinol* 2008;69:497–505.
- [77] Raue F. German medullary thyroid carcinoma/multiple endocrine neoplasia registry. German MTC/MEN Study Group. Medullary Thyroid Carcinoma/Multiple Endocrine Neoplasia Type 2. *Langenbecks Arch Surg* 1998;383:334–336.

- [78] Ansell SM, Grant CS, Habermann TM. Primary thyroid lymphoma. *Semin Oncol* 1999;26:316–323.
- [79] Widder S, Pasiaka JL. Primary thyroid lymphomas. *Curr Treat Options Oncol* 2004;5:307–313.
- [80] Holm L-E, Blomgren H, Löwhagen T. Cancer risks in patients with chronic lymphocytic thyroiditis. *New Engl J Med* 1985;312:601–604.
- [81] Kato I, Tajima K, Suchi T, et al. Chronic thyroiditis as a risk factor of B-cell lymphoma in the thyroid gland. *Japan J Cancer Res* 1985;76:1085–1090.
- [82] Chai YJ, Hong JH, Koo DH, et al. Clinicopathological characteristics and treatment outcomes of 38 cases of primary thyroid lymphoma: a multicenter study. *Ann Surg Treat Res* 2015;89:295.
- [83] Green LD, Mack L, Pasiaka JL. Anaplastic thyroid cancer and primary thyroid lymphoma: a review of these rare thyroid malignancies. *J Surg Oncol* 2006;94:725–736.
- [84] Nakadate M, Yoshida K, Ishii A, et al. Is 18F-FDG PET/CT useful for distinguishing between primary thyroid lymphoma and chronic thyroiditis? *Clin Nucl Med* 2013;38:709–714.
- [85] Wang Z, Fu B, Xiao Y, et al. Primary thyroid lymphoma has different sonographic and color Doppler features compared to nodular goiter. *J Ultrasound Med* 2015;34:317–323.
- [86] Sharma A, Jasim S, Reading CC, et al. Clinical presentation and diagnostic challenges of thyroid lymphoma: a cohort study. *Thyroid* 2016;26:1061–1067.
- [87] Matsuda M, Sone H, Koyama H, et al. Fine-needle aspiration cytology of malignant lymphoma of the thyroid. *Diagn Cytopathol* 1987;3:244–249.
- [88] Alzouebi M, Goepel JR, Horsman JM, et al. Primary thyroid lymphoma: the 40 year experience of a UK lymphoma treatment centre. *Int J Oncol* 2012;40:2075–2080.
- [89] Walsh S, Lowery AJ, Evoy D, et al. Thyroid lymphoma: recent advances in diagnosis and optimal management strategies. *Oncologist* 2013;18:994–1003.
- [90] Salhany KE, Pietra GG. Extranodal lymphoid disorders. *Am J Clin Pathol* 1993;99:472–485.
- [91] Derringer GA, Thompson LDR, Frommelt RA, et al. Malignant lymphoma of the thyroid gland. *Am J Surg Pathol* 2000;24:623–639.
- [92] Tsang RW. Localized mucosa-associated lymphoid tissue lymphoma treated with radiation therapy has excellent clinical outcome. *J Clin Oncol* 2003;21:4157–4164.
- [93] Thieblemont C, Mayer A, Dumontet C, et al. Primary thyroid lymphoma is a heterogeneous disease. *J Clin Endocrinol Metab* 2002;87:105–111.
- [94] Sakorafas GH, Kokkoris P, Farley DR. Primary thyroid lymphoma. *Surg Oncol* 2010;19:e124–e129.
- [95] Devine RM, Edis AJ, Banks PM. Primary lymphoma of the thyroid: a review of the Mayo Clinic experience through 1978. *World J Surg* 1981;5:33–38.
- [96] Rasbach DA, Mondschein MS, Harris NL, et al. Malignant lymphoma of the thyroid gland: a clinical and pathologic study of twenty cases. *Surgery* 1985;98:1166–1170.
- [97] Watanabe N, Narimatsu H, Noh JY, et al. Rituximab-including combined modality treatment for primary thyroid lymphoma: an effective regimen for elderly patients. *Thyroid* 2014;24:994–999.
- [98] Surov A, Holzhausen HJ, Machens A, et al. Imaging findings of thyroidal sarcoma. *Clin Imaging* 2014;38:826–830.
- [99] Thompson LDR, Wenig BM, Adair CF, et al. Primary smooth muscle tumors of the thyroid gland. *Cancer* 1997;79:579–587.
- [100] Bula G, Waler J, Niemiec A, et al. Unusual malignant thyroid tumours – a clinical study of 20 cases. *Acta Chir Belg* 2008;108:702–707.
- [101] Shah AA, Otori NP, Yip L, et al. Epithelioid hemangioendothelioma: a rare primary thyroid tumor with confirmation of WWTR1 and CAMTA1 rearrangements. *Endocr Pathol* 2016;27:147–152.
- [102] Dabelic N, Matesa N, Jukic T, et al. Primary fibrosarcoma of the thyroid gland: case report. *Acta Clin Croat* 2016;55:172–175.
- [103] Amal B, El Fatemi H, Souaf I, et al. A rare primary tumor of the thyroid gland: report a new case of leiomyosarcoma and literature review. *Diagn Pathol* 2013;8:36.
- [104] Shi RL, Qu N, Gao LL, et al. Primary synovial sarcoma of the thyroid with locally repeated relapses in short periods: a case report. *Biomed Rep* 2016.
- [105] Ozaslan E, Berk V, Baldane S, et al. Primary pleomorphic rhabdomyosarcoma of thyroid gland in an adult patient: a case report. *Eurasian J Med* 2016;48:69–72.
- [106] Kalitova P, Plzak J, Kodet R, et al. Angiosarcoma of the thyroid. *Eur Arch Oto-Rhino-Laryngol* 2008;266:903–905.
- [107] Rotellini M, Vezzosi V, Bianchi S. Epithelioid angiosarcoma of the thyroid: report of a case from an Italian non-alpine area and review of the literature. *Endocr Pathol* 2015;26:152–156.
- [108] Surov A, Gottschling S, Wienke A, et al. Primary thyroid sarcoma: a systematic review. *Anticancer Res* 2015;35:5185–5191.
- [109] Bayır Ö, Yilmazer D, Ersoy R, et al. An extremely rare case of thyroid malignancy from the non-Alpine region: angiosarcoma. *Int J Surgery Case Rep* 2016;19:92–96.
- [110] Petronella P, Scorzelli M, Luise R, et al. Primary thyroid angiosarcoma: an unusual localization. *World J Surg Oncol* 2012;10:73.
- [111] von Mehren M, Randall RL, Benjamin RS, et al. Soft tissue sarcoma, version 2.2016, NCCN Clinical Practice Guidelines in Oncology. *J Natl Compr Canc Netw* 2016;14:758–786.
- [112] Vitzthum LK, Brown LC, Rooney JW, et al. Head and neck soft tissue sarcomas treated with radiation therapy. *Rare Tumors* 2016;8:6165.
- [113] Shuman AG, Brennan MF, Palmer FL, et al. Soft tissue sarcoma of the head & neck: nomogram validation and analysis of staging systems. *J Surg Oncol* 2015;111:690–695.