

A reliable absorbable intranasal bolster for proper maintenance of fractured nasal bone position*

Yadranko Ducic¹, Peter A. Hilger²

¹ Department of Otolaryngology, University of Texas SouthWestern Medical Center, Dallas, Texas, USA, and Division of Otolaryngology and Facial Plastic Surgery, John Peter Smith Hospital, Fort Worth, Texas, USA

² Division of Facial Plastic and Reconstructive Surgery, University of Minnesota, Minneapolis, Minnesota, USA

SUMMARY

The maintenance of comminuted or otherwise unstable nasal bones in proper position following adequate operative reduction, may, on occasion, be a frustrating experience for both the patient and the surgeon. Migration of the fragments may compromise the aesthetic and functional results of well executed corrective nasal surgery. In this article, we will outline our successful, inexpensive approach to this occasionally challenging problem utilising an absorbable intranasal customised Surgicel bolster.

Key words: Intranasal bolster, nasal bone position

INTRODUCTION

Rhinoplasty, whether it be for the repair of traumatic, functional or cosmetic deformities, remains one of the most challenging surgical procedures. Thoughtful preoperative nasal framework analysis coupled with meticulous application of accepted surgical principles will most often lead to a satisfying result for both the surgeon and the patient. A major challenge of rhinoplasty remains controlling the surgically reconstructed nose during the healing phase. Postoperative shifting of framework elements can turn an otherwise well performed rhinoplasty into a surgical failure. One frustrating problem that is occasionally a major source of concern in the postoperative period is the unstable nasal bone that fails to maintain its proper position.

Traumatic fracture or surgical osteotomy both lead to a common endpoint of nasal bone mobility. These repositioned or newly positioned nasal bones will, on occasion, have a significant tendency to fall inwards in the early postoperative period. Comminuted nasal bones are likewise difficult to maintain in proper position. Although some have advocated fixation of fractured nasal bones with wires, plates or even halos, for the most part, these do not represent practical solutions in the routine treatment of unstable nasal bones (Illum et al., 1983; Kurihara and Kim, 1990; Lai, 1983; Wurman et al., 1983).

METHOD

Preventing migration of the fractured or osteotomised nasal bone fragments is the preferred method of management. We have had excellent success maintaining desirable nasal bone position with the use of Surgicel (Johnson and Johnson,

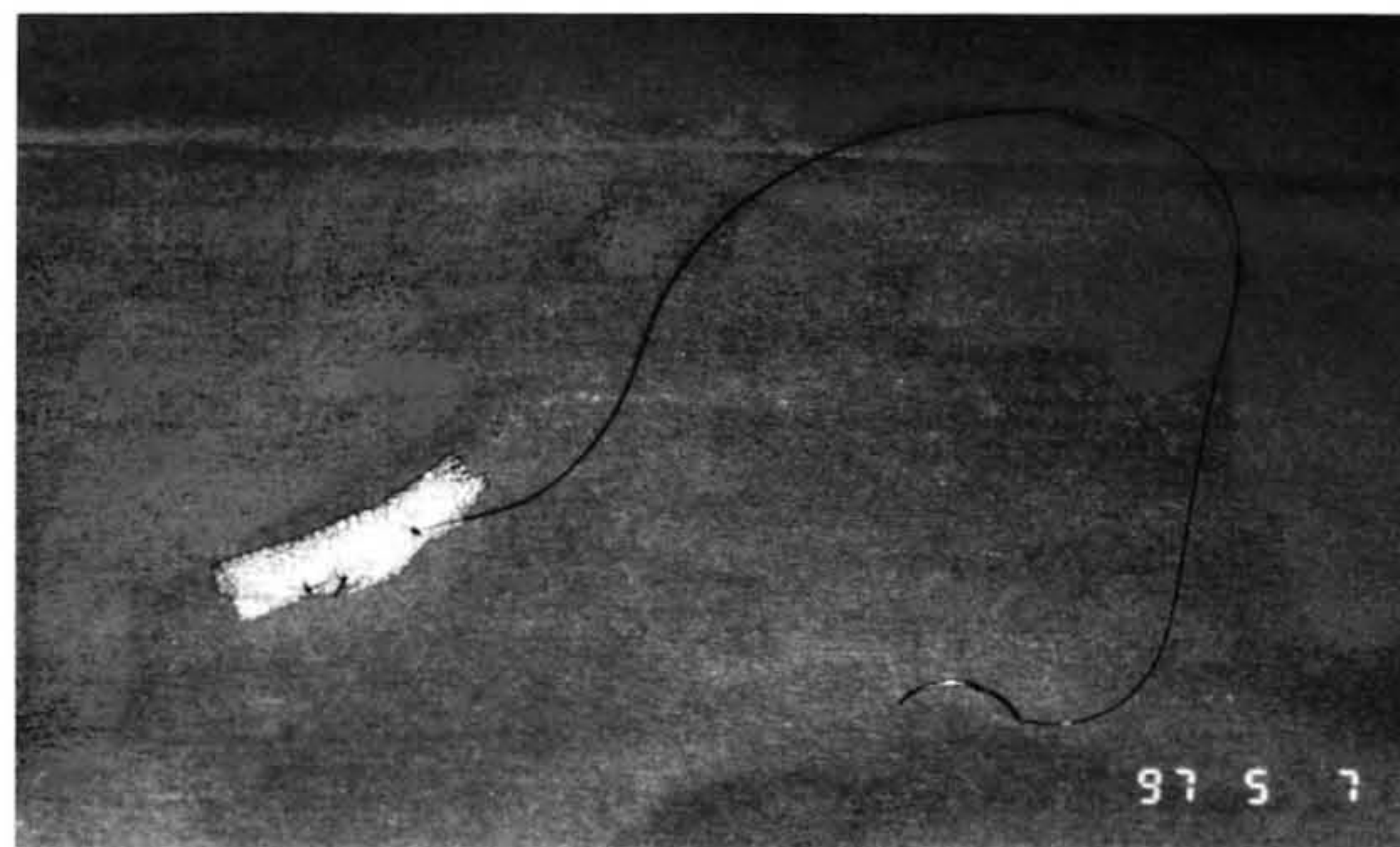


Figure 1. Custom fashioned Surgicel bolster. Note the suture attached to the bolster approximately one third the way along its length.

Arlington, TX, USA) which is custom-tailored into a reliable intranasal bolster. A one by two inch piece of Surgicel is made into a tight roll with a few 5.0 PDS (or other absorbable suture) sutures. This bolster should be at least 50% longer than the patient's nasal bones. Once the bolster has been fashioned, a 5.0 PDS suture is tied approximately one third of the way along the custom bolster (to provide for distribution of bolster pressure over the appropriate area on the undersurface of the nasal bone) and the needle is left attached to the suture (Figure 1). Next, a small needle driver is used to pass this needle intranasally through to the external nasal skin at the superior aspect of the fractured nasal bone close to the midline, as the bolster of Surgicel is put into position under the nasal bone (Figure 2). A medial osteotomy site or areas of nasal bone comminution also

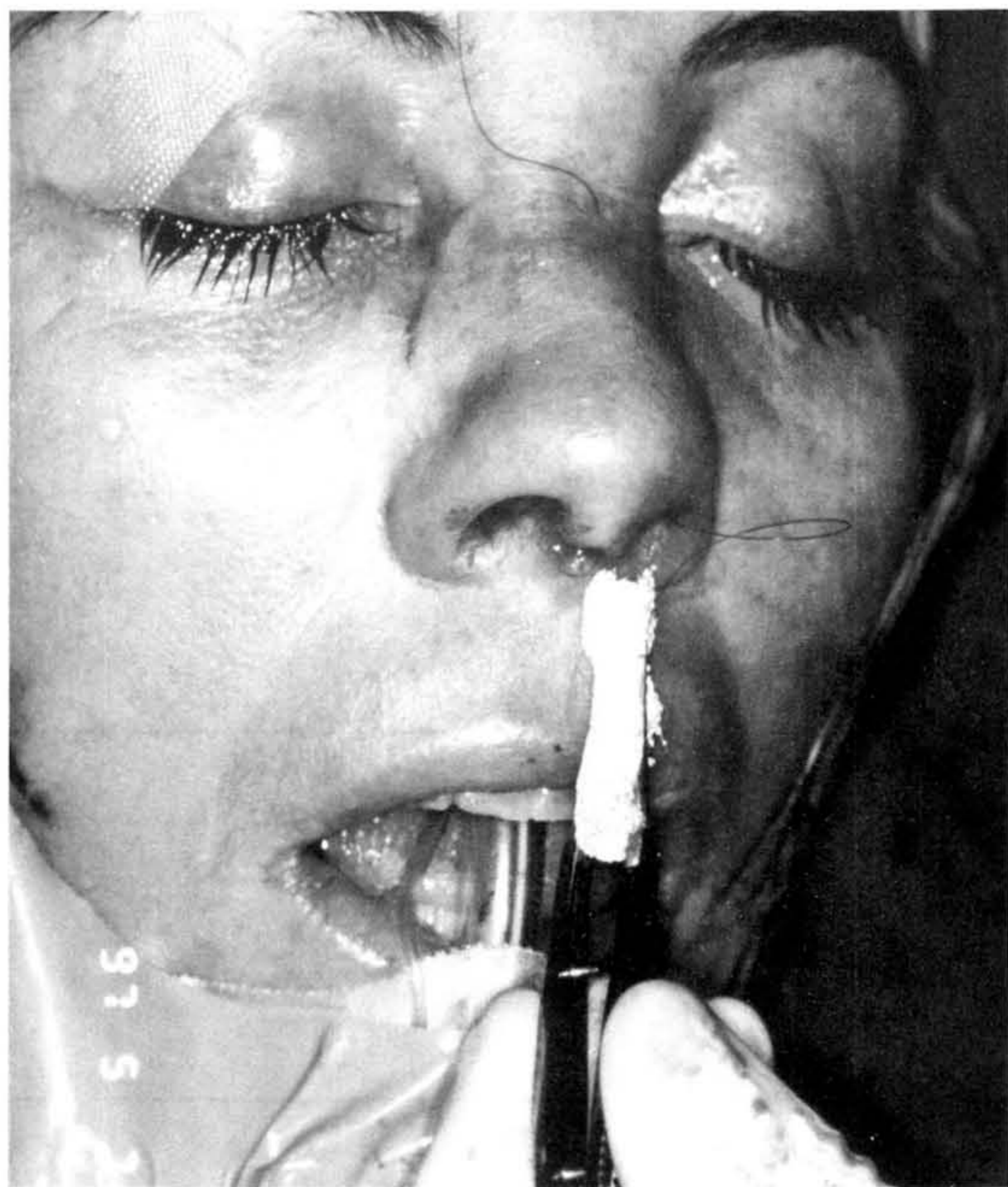

Figure 2. Suture has been passed transcutaneously and bolster is being manoeuvred into position.

serve as convenient areas to pass this transcutaneous suture. Tension is applied to this suture as steristrips are affixed to the nasal dorsum (Figure 3). This suture is now secured between two layers of steristrips, maintaining tension on the intranasal bolster of Surgicel. If necessary, a second suture can be secured to the inferior end of the surgicel roll and passed through the nasal dorsum. This is a useful method of providing two point fixation to the bolster that is occasionally useful for supporting the entire nasal sidewall. A thermoplastic external nasal dressing is finally applied to the nasal dorsum in the customary manner. The external nasal dressing is left in situ for five to seven days. Once it has been removed, the transcutaneous PDS sutures are simply transected flush with the skin surface. The patient is then placed on salt water nasal sprays which will, over the course of two to three days, result in gradual dissolution of the Surgicel bolster.

DISCUSSION

Surgicel is oxidised regenerated cellulose that is most often used as an absorbable hemostatic agent. When it is secured in position as described, it molds quite nicely to the undersurface of the nasal bone or nasal bone fragments. In the immediate postoperative period, it will desiccate forming a firm cast as support for the nasal bones. No nasal packing is necessary to maintain its position. Thus, airway patency is assured and patient comfort increased. At the time of removal of the external nasal dressing (steristrips and thermoplastic dressing) the short segment of the transcutaneous PDS suture is trimmed flush with the skin of the nasal dorsum. The intranasal Surgicel bolster is allowed to pass on its own. This generally occurs by the end of

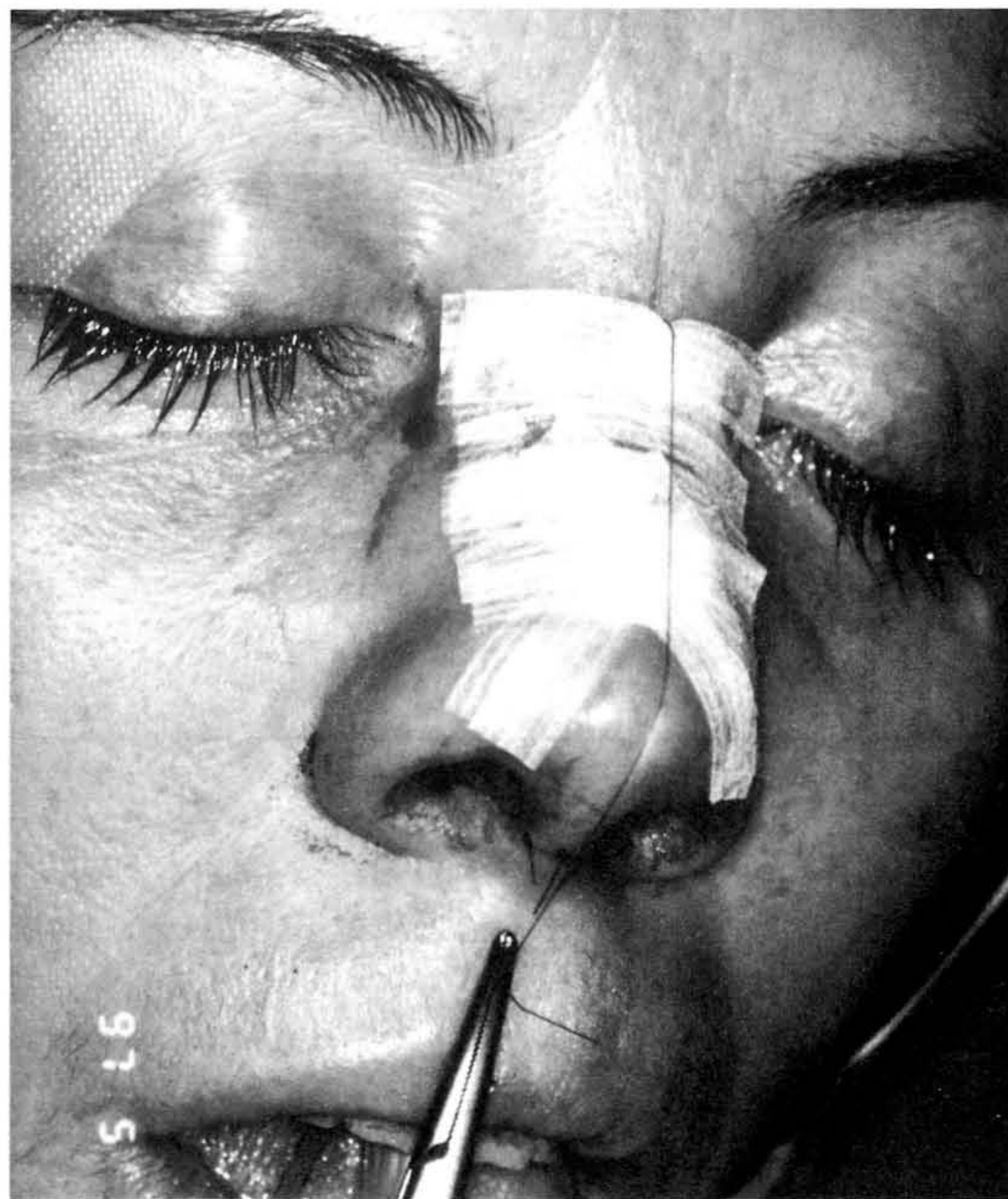

Figure 3. Dorsal nasal steristrips being applied while tension is maintained on retention suture. A second layer of steristrips on top of the suture will assure maintenance of tension on the intranasal bolster.

the second postoperative week. One may utilise this technique unilaterally or bilaterally, as the need dictates.

We have used the outlined technique in difficult, comminuted and excessively mobile nasal bones after both trauma and during traditional rhinoplasty in excess of sixty patients over the past four years. We have had no problems with early postoperative shifting or migration of nasal bone fragments. The excellent maintenance of position, in all cases, is impressive considering the fact that we do not use this bolster technique in routine cases. It is only utilised in problem cases where significant comminution is present or where there is excessive nasal bone mobility after fracture or osteotomy.

In summary, this absorbable intranasal bolster is a simple, inexpensive, expeditious technique. Patient acceptance is very high, both in terms of comfort and, aesthetic appeal.

REFERENCES

1. Illum P, Kristensen KS, Jorgensen R, Pedersen CB (1983) Role of fixation in the treatment of nasal fractures. *Clin Otolaryngol* 8:191-195.
2. Kurihara K, Kim K (1990) Open reduction and interfragment wire fixation of comminuted nasal fractures. *Ann Plast Surg* 24:179-185.
3. Lai S (1983) Suspension and traction appliance for nasal, zygomaticomaxillary complex and zygomatic arch fractures. *J Oral Maxillofac Surg* 41:133-134.
4. Wurman LH, Sack GJ, Flannery JV (1983) Halo external fixation of nasal fractures. *Laryngoscope* 93:1212-1216.

Dr. Y. Ducic
Dept. of Surgery
John Peter Smith Hospital
1500 South Main street
Texas USA 76104
Tel./fax: 817-4989482